

Feasibility of Triple Imaging Vasodilator Stress Echo in Patients with Suspected Coronary Artery Disease

Factibilidad del eco estrés vasodilatador de triple imagen en pacientes con sospecha de enfermedad coronaria

QUIRINO CIAMPI¹, MARCO PATERNI², BRUNO VILLARI¹, EUGENIO PICANO²

ABSTRACT

Background: Regional wall motion abnormalities (RWMA) are the diagnostic cornerstone of stress echo, but the positivity rate has been declining over the last decades. Additional information is obtained with simultaneous assessment of coronary flow velocity reserve (CFVR) on left anterior descending coronary artery and global left ventricular contractile reserve (LVCR) from the systolic pressure/end-systolic volume relationship.

Objective: The aim of this study was to assess the feasibility of triple imaging (RWMA + LVCR + CFVR) during dipyridamole stress echo.

Methods: We enrolled 40 consecutive patients (30 men; 62±11 years, mean ejection fraction: 62±7%) referred to testing for suspected coronary artery disease. All patients underwent dipyridamole (0.84 mg/kg in 6 min) stress echo. LVCR was defined as the ratio between peak and rest elastance index (cuff systolic blood pressure/left ventricular end-systolic volume from biplane Simpson method, normal values: > 1.0). CFVR was defined as the ratio between maximal vasodilation and rest peak diastolic flow velocity in the left anterior descending coronary artery (normal values >2.0).

Results: In 40 consecutive patients, interpretable images were obtained in 40/40 patients (100%) for RWMA, 40/40 (100%) for LVCR and 40/40 (100%) for CFVR. The positivity rate was 1/40 (2%) for RWMA, 4/40 (10%) for LVCR, 6/40 (15%) for CFVR and 9/40 (22.5%) with any of the three criteria combined. The average additional imaging time at peak stress after completion of RWMA imaging was 45 seconds for CFVR; no extra-time was required for LVCR. The average off-line analysis time was 30 seconds for RWMA, 55 seconds for LVCR, and 15 seconds for CFVR.

Conclusions: Triple imaging vasodilator stress echo was highly feasible and non-time consuming. Abnormal values are more frequently found with CFVR and LVCR than with RWMA. Triple imaging might become the new diagnostic standard in stress echo, and a larger scale validation is now ongoing in the Italian Stress echo 2020 multicenter study.

Key words: Echocardiography, Stress - Dipyridamole - Blood Flow Velocity - Myocardial Contraction

RESUMEN

Introducción: La detección de anomalías de la motilidad parietal regional (AMPR) es la base del diagnóstico por eco estrés, pero la tasa de positividad ha ido disminuyendo en las últimas décadas. Por otra parte, se obtiene información adicional de la evaluación simultánea de la reserva de la velocidad de flujo coronario (RVFC) de la arteria coronaria descendente anterior y de la reserva contractil del ventrículo izquierdo (RCVI) a través de la relación presión-volumen de fin de sístole.

Objetivo: Evaluar la posibilidad de obtener triple imagen (AMPR + RVFC + RCVI) durante el eco estrés con dipiridamol.

Material y métodos: Se enrolaron 40 pacientes consecutivos (30 hombres, con edad media de 62 ± 11 años y fracción de eyección media del 62% ± 7%), derivados a estudio por sospecha de enfermedad coronaria. Todos los pacientes fueron sometidos a eco estrés con dipiridamol (0,84 mg/kg en 6 min). La RCVI se definió como la relación entre el índice de elastancia máxima y de reposo (presión arterial sistólica medida por esfigmomanometría/volumen de fin de sístole del ventrículo izquierdo por el método de Simpson biplano, con valores normales > 1,0). A su vez, la RVFC se definió como la relación entre la vasodilatación máxima y la velocidad máxima del flujo diastólico de reposo en la arteria coronaria descendente anterior (valores normales > 2,0).

Resultados: Se obtuvieron imágenes viables en 40/40 pacientes (100%) para las AMPR, 40/40 (100%) para la RCVI y 40/40 (100%) para la RVFC. La tasa de positividad fue de 1/40 (2%) para las AMPR, 4/40 (10%) para la RCVI, 6/40 (15%) para la RVFC y 9/40 (22,5%) combinando cualquiera de los tres criterios. El promedio de tiempo adicional de adquisición de imágenes en el estrés pico luego de completar la adquisición de AMPR fue de 45 segundos para la RVFC, y no se requirió tiempo extra para la RCVI. El tiempo promedio de análisis off-line fue de 30 segundos para las AMPR, de 55 segundos para la RCVI y de 15 segundos para la RVFC.

Conclusiones: El eco estrés vasodilatador de triple imagen es altamente factible y no insume tiempo adicional. La RVFC y la RCVI proporcionan valores anormales más frecuentemente que las AMPR. La triple imagen podría convertirse en el nuevo referente diagnóstico del eco estrés. Actualmente se está llevando a cabo una validación a gran escala en el estudio multicéntrico italiano Stress echo 2020.

Palabras clave: Ecocardiografía de estrés - Dipiridamol - Velocidad del flujo sanguíneo - Contracción miocárdica

REV ARGENT CARDIOL 2016;84:310-316. <http://dx.doi.org/10.7775/rac.v84.i4.9063>

Received: 05/06/2016 – Accepted: 06/27/2016

Address for reprints: Eugenio Picano, MD, PhD - Istituto di Fisiologia Clinica del Consiglio Nazionale delle Ricerche - Via Savi, 8 - 56124 - Pisa, Italia

Ospedale Fatebenefratelli, Division of Cardiology¹. Benevento, Italia - Istituto di Fisiologia Clinica at CNR². Pisa, Italy

Abbreviations

2D	Two-dimensional	LVCR	Left ventricular contractile reserve
CAD	Coronary artery disease	RWMA	Regional wall motion abnormalities
CFVR	Coronary flow velocity reserve	SE	Stress echocardiography
ESV	End-systolic volume	WMSI	Wall motion score index

INTRODUCTION

Both specialty recommendations (1, 2) and general cardiology guidelines (3, 4) recommend stress echocardiography (SE) with either exercise or pharmacological stress as a primary tool for evaluating patients with established or suspected coronary artery disease (CAD). The cornerstone of SE diagnosis is the induction of regional wall motion abnormalities (RWMA). However, the potentially valuable information provided by SE extends beyond regional wall motion. In vasodilator stress, a clear step-up in diagnostic sensitivity (with a modest loss in specificity) is obtained with assessment of coronary flow velocity reserve (CFVR) in the left anterior descending coronary artery. (5-7) Further gains in sensitivity can be achieved by non-invasive assessment of left ventricular contractile reserve (LVCR) through changes in left ventricular elastance, a load-independent index of left ventricular contractility. (8) The combination of CFVR and LVCR with standard RWMA might improve the diagnostic and prognostic yield of SE, whose positivity rate based on RWMA has been declining steadily in recent decades. (9) Promising, pioneering, proof-of-concept data have been reported with the combination of RWMA first with CFVR (10) and later with CFVR and 2D strain in one test by Lowenstein et al., (11) clearing the path to a triple imaging approach combining the standard test based on RWMA with a more quantitative insight into coronary microcirculation and regional myocardial contractility. All this can now be done in only one imaging test which is fast, safe, radiation-free, inexpensive, objective, and with high diagnostic precision. (8, 12) In the original formulation, (11) the triple imaging SE relied on 2D strain for quantitative contractility assessment, which implies mastering an additional technology such as 2D strain, more demanding and vulnerable to artifacts than simple 2D imaging. (13) We decided to use, instead, a global contractility index such as LVCR, (8) measured as peak stress/rest ratio of left ventricular elastance, an afterload and preload independent index of global left ventricular contractility. Left ventricular contractile reserve has strong pathophysiological rationale, only requires 2D imaging and systolic blood pressure measurement by cuff sphygmomanometer, is simpler and cheaper than 2D strain imaging, and has proven incremental prognostic value over RWMA and CFVR, separately considered, during different forms of SE, from pacing to exercise, from dobutamine to dipyridamole. (14-19) The overarching aim is to gain insight into

three different variables (RWMA, LVCR and CFVR) all in the same setting, each one with different and complementary information, since RWMA occurs mainly for functionally important epicardial CAD, LVCR can be impaired for epicardial stenosis and primary myocardial disease, and CFVR for both epicardial stenosis and microvascular disease: as a matter of fact, three different tests into one.

Although promising at this stage, we still need more data on the feasibility of performing it in unselected patients, the additional imaging and analysis time, and the variability of the triple imaging SE approach when deployed in the field. The aim of this study was to assess the feasibility, positivity rate and variability of triple imaging vasodilator stress echocardiography when used routinely in a busy SE primary care referral laboratory.

METHODS

We enrolled 40 consecutive patients (29 men; 62 ± 10 years, mean ejection fraction: $62 \pm 7\%$) referred to Benevento Fatebenefratelli Hospital SE laboratory for suspected coronary artery disease: 25 patients for angina, 10 patients for non-diagnostic exercise test, and 5 patients for left bundle branch block. According to selection criteria, all patients had normal regional and global resting function and low-to-intermediate pre-test likelihood of coronary artery disease, representing true diagnostic challenges. All patients underwent dipyridamole (0.84 mg/kg in $6'$) SE.

Regional wall motion abnormalities

A 17-segment model of the left ventricle was used. Each segment was scored from 1 normal to 4, dyskinetic, to generate a wall motion score index (WMSI) at rest and peak stress (1). Positivity was associated with RWMA in at least 2 contiguous segments (peak WMSI > WMSI). An example of a RWMA report is shown in Figure 1.

Global left ventricular contractile reserve

Left ventricular contractile reserve was defined as the ratio between peak and resting elastance, measured as the difference between SE resting and peak SE values of the ratio between systolic pressure (evaluated by aneroid cuff sphygmomanometer) and end-systolic volume (ESV) normalized by body surface area. End-systolic volume was obtained offline from apical four- and two-chamber views using the biplane Simpson method. Only representative cycles with optimal endocardial visualization were measured and the average of three measurements was recorded. The endocardial border was traced, excluding the papillary muscles. The frame with the smallest LV chamber was considered as end systolic frame. (19-21) A LVCR value <1.0 was considered abnormal. An example of a LVCR positivity report is shown in Figure 2.

Coronary flow velocity reserve

Coronary flow velocity reserve was assessed during the standard SE examination by intermittent imaging of both wall motion and left anterior descending coronary artery flow. (1) Coronary flow in the mid-distal portion of the left anterior descending coronary artery was explored in the low parasternal long-axis section under the guidance of color Doppler flow mapping. (1) All studies were digitally stored to simplify off-line reviewing and measurements. Coronary flow parameters were analyzed off-line using the built-in calculation package of the ultrasound unit. Flow velocities were measured more than twice for each study, namely at baseline and at peak stress (before aminophylline injection). At each time point, 3 optimal profiles of peak diastolic Doppler flow velocities were measured, and the results were averaged. Coronary flow velocity reserve was defined as the ratio between hyperemic peak and baseline peak diastolic

coronary flow velocities. A CFVR value <2.0 was considered abnormal. An example of a CFVR positivity report is shown in Figure 3.

The previously assessed intra- and inter-observer variability for RWMA, CFVR and LVCR assessment was consistently <5% and <10%, respectively, as formerly shown. (6, 8, 15)

Statistical analysis

Continuous variables are expressed as mean±standard deviation. Categorical variables are presented as counts and percentages.

Ethical considerations

The study was evaluated and approved by an institutional Research Committee. An informed consent was signed by each patient included in the study.

Fig. 1. Example of a positivity report based on regional wall motion abnormalities with the stress echo 2020 software. At baseline, normal function is seen (all segments are green, corresponding to a score=1). At peak stress, septal and apical wall motion abnormalities are observed, with akinetic (score=2, in yellow in the bull's eye report) or dyskinetic (score=3, in red) segments in the left anterior descending coronary artery territory.

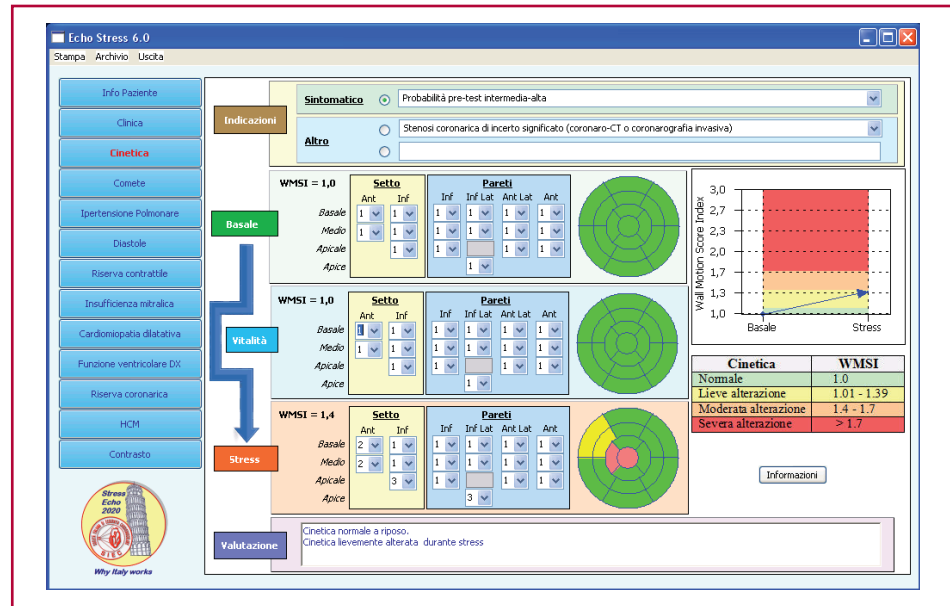
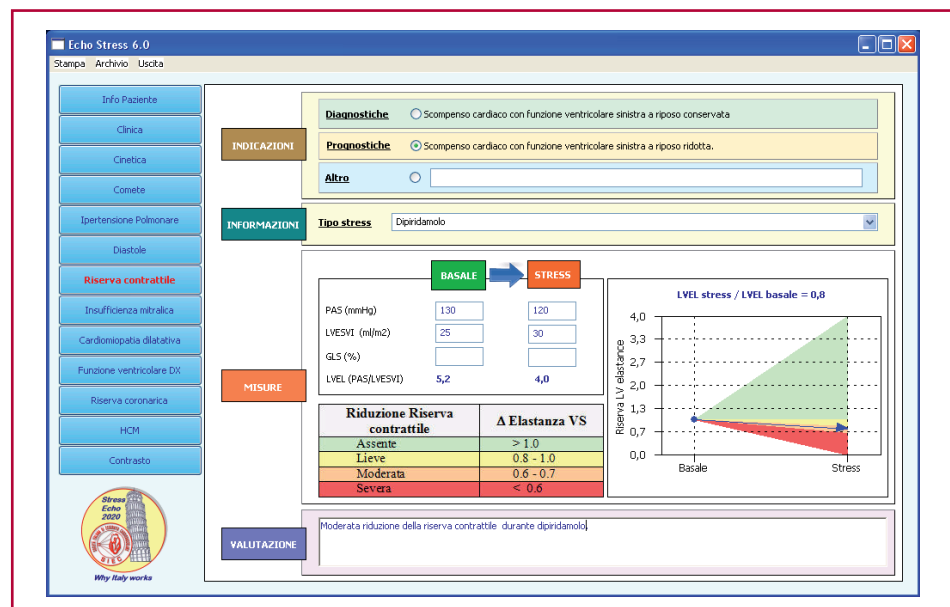


Fig. 2. Example of a positivity report based on reduced left ventricular contractile reserve (LVCR) with the stress echo 2020 software. This patient has a resting and stress left ventricular elastance (i.e., the ratio between systolic blood pressure and end-systolic volume) ratio <1.0, which is considered abnormal during vasodilator stress.



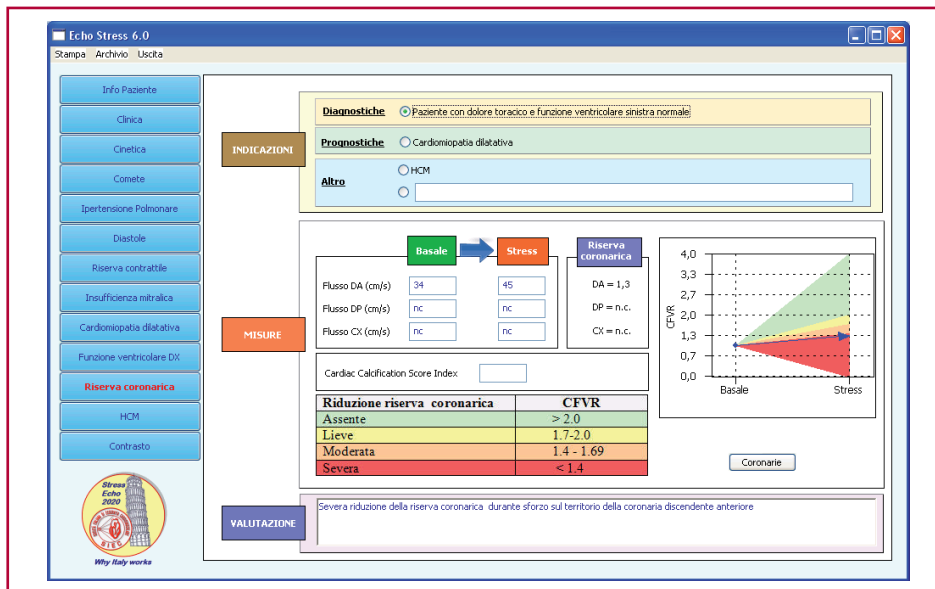


Fig. 3. Example of a positivity report based on reduced coronary flow velocity reserve (CFVR) with the stress echo 2020 software. This patient had a CFVR on the left anterior descending coronary artery <2.0, which is considered abnormal during vasodilator stress

RESULTS

The main clinical and resting echocardiographic features of the study patients are reported in Table 1.

The average additional imaging time at peak stress after completion of RWMA imaging was 45 seconds for CFVR, and no extra-time was required for LVCR. The average off-line analysis time was 30 seconds for RWMA, 55 seconds for LVCR, and 15 seconds for CFVR.

In 40 consecutive patients, interpretable images were obtained in 40/40 patients (100%) for RWMA, 40/40 (100 %) for CFVR and 40/40 (100%) for LVCR. The positivity rate was 1/40 (2 %) for RWMA, 6/40 (15%) for CFVR and 4/40 (10%) for LVCR, with 2 patients showing more than one positivity criteria (Figure 4). If any of the positivity criteria is considered, the positivity rate was 9/40 (22.5 %).

Table 1. Baseline clinical and echocardiographic characteristics (n=40).

Age, years	62±1
Men, n (%)	30 (75)
History of hypertension, n (%)	30 (75)
History of diabetes, n (%)	8 (20)
History of dyslipidemia, n (%)	21 (52)
Left ventricular end-diastolic volume, ml	72±18
Left ventricular end-systolic volume, ml	28±12
Left ventricular end-systolic volume index, ml/m2	16±8
Left ventricular ejection fraction, %	62±7
Medication	
ACE inhibitors, n (%)	28 (70)
β-blockers, n (%)	20 (50)

ACE: Angiotensin-converting enzyme

DISCUSSION

We have shown the high feasibility, short additional imaging time and analysis time, and low variability of the triple imaging SE approach, possibly destined to become the “third generation” state-of-the-art SE modality. During the test, all stages of evolution are recapitulated and summarized in a new test, where new information adds up on the shoulder of previous ones. The evaluation of RWMA is the first generation (and still working) SE test, proposed over 30 years ago, the only one recognized by general guidelines, (3, 4) and still up and running: it represents the standard or conventional single imaging approach. Coronary flow velocity reserve is the second generation SE test, first proposed in combination with RWMA over 10 years ago, and now recommended by specialty guidelines when technology and available expertise allow it. (2) Left ventricular contractile reserve is the third generation test, proposed with RWMA and CFVR 5 years ago, or just in combination with RWMA (without CFVR) over 10 years ago. It is the triple imaging ap-

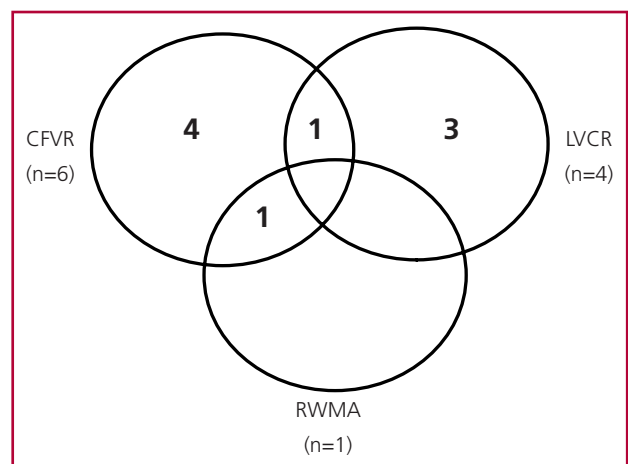


Fig. 4. Venn diagram showing the positivity rate of regional wall motion abnormalities (RWMA) (1 out of 40), reduced left ventricular contractile reserve (LVCR) (4 out of 40) and reduced coronary flow velocity reserve (CFVR) (6 out of 40) in 40 consecutive patients. Positivity is rarer with RWMA, more frequent with CFVR, and intermediate with LVCR. Two patients have two concurrent positivity criteria.

proach: RWMA, CFVR and LVCR in a one-stop shop, “three birds with one stone”. Regional wall motion abnormalities are more frequently linked to a significant epicardial artery flow-limiting stenosis. Coronary flow velocity reserve can be impaired even when the epicardial artery stenosis is absent, if the coronary microcirculation is altered. Left ventricular contractile reserve can be abnormal with either epicardial stenosis or coronary microcirculation abnormalities but, also and mostly, senses a primary myocardial disease impairing the inotropic reserve, which may occur independently of underlying macro- or micro-vascular disease. The three parameters converge into a single test with the triple imaging SE test.

Comparison with previous studies

Our findings are consistent with previous studies from different groups showing the high feasibility of both CFVR and LVCR during vasodilator stress. Both indices detect abnormalities in the absence of RWMA, which may have diagnostic (5-8) and prognostic (8, 14-16, 20-30) value in a variety of patient subsets. No comparative head-to-head data are available on the three indices obtained simultaneously by the same operator during the same stress study in the same patient. Only a pioneering study by Lowenstein et al. proposed an integrated approach with triple imaging. (11) In that study, the quantitative information on contractility was obtained with the longitudinal-radial-circumferential strain measurement, which is a comprehensive but technically demanding approach, also vulnerable to artifacts. More recently, other groups have shown the added diagnostic value of global longitudinal strain over RWMA during dipyridamole stress, but without information on CFVR. (31) We used the same overall philosophy of triple imaging but with a somewhat simplified approach to quantify global contractility, as first proposed by Bombardini et al. (8) 2D strain uses a dedicated (and expensive) technology, whereas LVCR is based on simpler 2D assessment of end-systolic volumes. Newer indices are based on parameters which may be more difficult to acquire but are certainly more quantitative and easier to measure than the exquisitely qualitative and subjective RWMA assessment.

Study limitations

The sample size is limited, and the absence of diagnostic and prognostic gold standards such as coronary angiography and follow-up information does not allow assessing the incremental diagnostic and prognostic value of the new parameters. However, this has already been demonstrated separately for both CFVR (5-7) and LVCR, (8) and was not the aim of the present study. The findings apply to dipyridamole stress, and not necessarily extend to other stressors such as adenosine, dobutamine and exercise, which are associated in variable amounts to factors degrading the stress image quality, such as hyperventilation, tachycardia

and hypercontractility. (2) Different stresses may have different feasibility rate, diagnostic cut-off points and prognostic yield, since it is entirely possible that lower normal values of CFVR and higher values of LVCR are required for dobutamine and exercise stresses, which have lower vasodilatory and higher inotropic effect than dipyridamole or adenosine. (32) The present study only addressed the issue of feasibility, practicality and reproducibility of the new third-generation SE test. A large scale validation is certainly needed at this point and presently ongoing, since triple imaging SE is one the 10 subprojects of the Italian SE 2020 multicenter study coordinated by the Pisa National Research Council and endorsed by the Italian Society of Echocardiography, with planned recruitment for this specific subproject of around 5,000 patients enrolled by 2020 by more than 100 accredited Italian SE laboratories. These data are needed to translate the proof of concept of the present feasibility study into the fruit of diagnostic and prognostic effectiveness when the technique is deployed in the field, on the footsteps of multicenter studies that proved the safety, feasibility and value of first-generation multicenter studies based upon RWMA. (33-35)

Clinical implications

The triple imaging, third-generation SE is attractively simple, fast and potentially informative. It enters now the chain of scientific and clinical validation required to become the state-of-the-art SE, with RWMA, CFVR and LVCR together in the same sitting with one test. SE is ready once more to undergo a methodological mutation, adapting to the changing profile of patients referred for testing and now usually kept under anti-anginal therapy. In the updated version, triple-imaging SE will exploit at the fullest its advantages of low cost, absence of radiation, (36) and prodigious versatility (37) of the technique, eventually coming closer to the ideal test: more operator-independent, more quantitative, and more informative. Ischemic heart disease can today present in the stress testing lab under many different shapes, targeting primarily (but usually in various combinations) epicardial stenosis or coronary microcirculation or the myocardium, and each of these targets can asymmetrically affect the different diagnostic tools in case of selective damage: epicardial stenosis will induce RWMA, coronary microcirculation damage, a reduction in CFVR, and myocardial damage or fibrosis, LVCR impairment. Now, they all can be panoramically and simultaneously explored with the triple imaging SE test.

CONCLUSIONS

Triple imaging vasodilator stress echocardiography is highly feasible and non-time consuming. Abnormal values are more frequently provided by CFVR and LVCR than by RWMA. Triple imaging could become the new diagnostic standard of stress echocardiography.

Conflicts of interest

None declared.

(See authors' conflicts of interest forms in the website/Supplementary material).

REFERENCES

- Pelikka PA, Nagueh SF, Elhendy AA, Kuehl CA, Sawada SG; American Society of Echocardiography. American Society of Echocardiography recommendations for performance, interpretation, and application of stress echocardiography. *J Am Soc Echocardiogr* 2007;20:1021-41. <http://doi.org/bn7jkkf>
- Sicari R, Nihoyannopoulos P, Evangelista A, Kasprzak J, Lancellotti P, Poldermans D, et al; European Association of Echocardiography. Stress echocardiography expert consensus statement: European Association of Echocardiography (EAE) (a registered branch of the ESC). *Eur J Echocardiogr* 2008;9:415-37. <http://doi.org/dvxxvq8>
- Task Force Members, Montalescot G, Sechtem U, Achenbach S, Andreotti F, Arden C, Budaj A, et al; ESC Committee for Practice Guidelines, Zamorano JL, Achenbach S, Baumgartner H, Bax JJ, Bueno H, Dean V, et al; Document Reviewers, Knuuti J, Valgimigli M, Bueno H, Claeys VJ, Donner-Banzhoff N, Erol C, et al. 2013 ESC guidelines on the management of stable coronary artery disease: the Task Force on the management of stable coronary artery disease of the European Society of Cardiology. *Eur Heart J* 2013;34:2949-3003. <http://doi.org/f3nm58>
- Wolk MJ, Bailey SR, Doherty JU, Douglas PS, Hendel RC, Kramer CM, et al; American College of Cardiology Foundation Appropriate Use Criteria Task Force. ACCF/AHA/ASE/ASNC/HFSA/HRS/SCAI/SCCT/SCMR/STS 2013 multimodality appropriate use criteria for the detection and risk assessment of stable ischemic heart disease: a report of the American College of Cardiology Foundation Appropriate Use Criteria Task Force, American Heart Association, American Society of Echocardiography, American Society of Nuclear Cardiology, Heart Failure Society of America, Heart Rhythm Society, Society for Cardiovascular Angiography and Interventions, Society of Cardiovascular Computed Tomography, Society for Cardiovascular Magnetic Resonance, and Society of Thoracic Surgeons. *J Am Coll Cardiol* 2014;63:380-406. <http://doi.org/f2qrm3>
- Lowenstein J, Tiano C, Marquez G, Presti C, Quiroz C. Simultaneous analysis of wall motion and coronary flow reserve of the left anterior descending coronary artery by transthoracic doppler echocardiography during dipyridamole stress echocardiography. *J Am Soc Echocardiogr* 2003;16:607-13. <http://doi.org/d2g25c>
- Rigo F, Richieri M, Pasanisi E, Cutaia V, Zanella C, Della Valentina P, et al. Usefulness of coronary flow reserve over regional wall motion when added to dual-imaging dipyridamole echocardiography. *Am J Cardiol* 2003;91:269-73. <http://doi.org/d2g3bk>
- Nohtomi Y, Takeuchi M, Nagasawa K, Arimura K, Miyata K, Kuwata K, et al. Simultaneous assessment of wall motion and coronary flow velocity in the left anterior descending coronary artery during dipyridamole stress echocardiography. *J Am Soc Echocardiogr* 2003;16:457-63. <http://doi.org/bb7knx>
- Bombardini T, Gherardi S, Marraccini P, Schlueter MC, Sicari R, Picano E. The incremental diagnostic value of coronary flow reserve and left ventricular elastance during high-dose dipyridamole stress echocardiography in patients with normal wall motion at rest. *Int J Cardiol* 2013;168:1683-4. <http://doi.org/bkge>
- Bouzas-Mosquera A, Peteiro J, Broullón FJ, Calviño-Santos R, Mosquera VX, Sánchez-Fernández G, et al. Temporal changes in the use and results of exercise echocardiography. *Eur Heart J Cardiovasc Imaging* 2015;16:1207-12. <http://doi.org/bkgd>
- Lowenstein JA, Tiano C, Márquez G, Presti C. Sensitivity increase of dipyridamole echo-stress with the simultaneous determination of contractility and coronary flow reserve of the anterior descending coronary artery by transthoracic Doppler echocardiography. *Rev Argent Cardiol* 2000;68:683-96.
- Lowenstein J, Darú V, Amor M, Carlessi A, Zambrana G, Descalzo M, et al. Simultaneous Analysis of Two-Dimensional Strain, Coronary Flow Reserve and Wall Motion during Dipyridamole Stress Echocardiography. Comparative Outcomes. *Rev Argent Cardiol* 2010;78:499-506.
- Picano E. ¿Es el comienzo del eco estrés de tercera generación? Editorial. *Rev Argent Cardiol* 2010;78:507-10.
- Pelikka PA, Douglas PS, Miller JG, Abraham TP, Baumann R, Buxton DB, et al. American Society of Echocardiography Cardiovascular technology and Research Summit: a roadmap for 2020. *J Am Soc Echocardiogr* 2013;26:325-38. <http://doi.org/bkgf>
- Grosu A, Bombardini T, Senni M, Duino V, Gori M, Picano E. End-systolic pressure/volume relationship during dobutamine stress echo: a prognostically useful non-invasive index of left ventricular contractility. *Eur Heart J* 2005;26:2404-12. <http://doi.org/cmhzr6>
- Cortigiani L, Bombardini T, Corbisiero A, Mazzoni A, Bovenzi F, Picano E. The additive prognostic value of end-systolic pressure-volume relation in patients with diabetes mellitus having negative dobutamine stress echocardiography by wall motion criteria. *Heart* 2009;95:1429-35. <http://doi.org/cqbrtj>
- Ciampi Q, Pratali L, Citro R, Villari B, Picano E, Sicari R. Clinical and prognostic role of pressure-volume relationship in the identification of responders to cardiac resynchronization therapy. *Am Heart J* 2010;160:906-14. <http://doi.org/fsgb9q>
- Bombardini T, Correia MJ, Cicerone C, Agricola E, Ripoli A, Picano E. Force-frequency relationship in the echocardiography laboratory: a noninvasive assessment of Bowditch treppe? *J Am Soc Echocardiogr* 2003;16:646-55. <http://doi.org/bjs84f>
- Bombardini T, Zoppè M, Ciampi Q, Cortigiani L, Agricola E, Salvadori S, et al. Myocardial contractility in the stress echo lab: from pathophysiological toy to clinical tool. *Cardiovasc Ultrasound* 2013;11:41. <http://doi.org/bkkg>
- Bombardini T, Mulieri LA, Salvadori S, Costantino MF, Scali MC, Marzilli M, et al. Pressure-volume relationship in the stress-echocardiography laboratory: does (left ventricular end-diastolic) size matter? *Rev Esp Cardiol* 2016. [Epub ahead of print]
- Rigo F, Cortigiani L, Pasanisi E, Richieri M, Cutaia V, Celestre M, et al. The additional prognostic value of coronary flow reserve on left anterior descending artery in patients with negative stress echo by wall motion criteria. A Transthoracic Vasodilator Stress Echocardiography Study. *Am Heart J* 2006;151:124-30. <http://doi.org/b2rx3k>
- Cortigiani L, Rigo F, Gherardi S, Bovenzi F, Molinaro S, Picano E, et al. Coronary flow reserve during dipyridamole stress echocardiography predicts mortality. *JACC Cardiovasc Imaging* 2012;5:1079-81. <http://doi.org/bkgh>
- Galderisi M, Cortigiani L, Picano E. The prognostic value of Doppler echocardiographic-derived coronary flow reserve is not affected by concomitant antiischemic therapy at the time of testing. *Am Heart J* 2008;156:573-9. <http://doi.org/bfkm86>
- Sicari R, Rigo F, Gherardi S, Galderisi M, Cortigiani L, Picano E. The prognostic value of Doppler echocardiographic-derived coronary flow reserve is not affected by concomitant antiischemic therapy at the time of testing. *Am Heart J* 2008;156:573-9. <http://doi.org/bfkm86>
- Cortigiani L, Rigo F, Gherardi S, Sicari R, Galderisi M, Bovenzi F, et al. Additional prognostic value of coronary flow reserve in diabetic and nondiabetic patients with negative dipyridamole stress echocardiography by wall motion criteria. *J Am Coll Cardiol* 2007;50:1354-61. <http://doi.org/cb5xp3>
- Lowenstein JA, Caniggia C, Rouse G, Amor M, Sánchez ME, Alasia D, et al. Coronary flow velocity reserve during pharmacologic stress echocardiography with normal contractility adds important prognostic value in diabetic and nondiabetic patients. *J Am Soc Echocardiogr* 2014;27:1113-9. <http://doi.org/bkgj>
- Cortigiani L, Rigo F, Galderisi M, Gherardi S, Bovenzi F, Picano E, et al. Diagnostic and prognostic value of Doppler echocardiographic coronary flow reserve in the left anterior descending artery in hypertensive and normotensive patients [corrected]. *Heart* 2011;97:1758-65. <http://doi.org/fwwwv5g>
- Cortigiani L, Rigo F, Gherardi S, Bovenzi F, Molinaro S, Picano E, et al. Prognostic implication of Doppler echocardiographic derived coronary flow reserve in patients with left bundle branch block. *Eur Heart J* 2013;34:364-73. <http://doi.org/bkgk>
- Rigo F, Gherardi S, Galderisi M, Pratali L, Cortigiani L, Sicari R, et al. The prognostic impact of coronary flow-reserve assessed by Doppler echocardiography in non-ischaemic dilated cardiomyopathy. *Eur Heart J* 2006;27:1319-23. <http://doi.org/bqwqtq>
- Cortigiani L, Rigo F, Gherardi S, Galderisi M, Sicari R, Picano E. Prognostic implications of coronary flow reserve on left anterior descending coronary artery in hypertrophic cardiomyopathy. *Am J*

Cardiol 2008;102:1718-23. <http://doi.org/d2s49b>

30. Lima MF, Mathias W Jr, Sbrano JC, de la Cruz VY, Abduch MC, Lima MS, et al. Prognostic value of coronary and microvascular flow reserve in patients with nonischemic dilated cardiomyopathy. *J Am Soc Echocardiogr* 2013;26:278-87. <http://doi.org/bkgm>

31. Cusmà-Piccione M, Zito C, Oreto L, D'Angelo M, Tripepi S, Di Bella G, et al. Longitudinal strain by automated function imaging detects single-vessel coronary artery disease in patients undergoing dipyridamole stress echocardiography. *J Am Soc Echocardiogr* 2015;28:1214-21. <http://doi.org/bkgn>

32. Picano E. Stress echocardiography. From pathophysiological toy to diagnostic tool. Point of view. *Circulation* 1992;85:1604-12. <http://doi.org/bkgp>

33. Picano E, Marini C, Pirelli S, Maffei S, Bolognese L, Chiriatti GP, et al, on behalf of the EPIC study group. Safety of intravenous high-dose dipyridamole echocardiography. *Am J Cardiol* 1992;70:252-56. <http://doi.org/bdvrb6>

34. Picano E, Mathias W Jr, Pingitore A, Bigi R, Previtali M, on behalf of the EDIC study group. Safety and tolerability of dobutamine-atropine stress echocardiography: a prospective, large scale, multicenter trial. *Lancet* 1994;344:1190-2. <http://doi.org/fnbtrw>

35. Picano E, Landi P, Bolognese L, Chiarandà G, Chiarella F, Seveso G, et al, on behalf of the EPIC study group. Prognostic value of dipyridamole-echocardiography early after uncomplicated myocardial infarction: a large scale multicenter trial. *Am J Med* 1993;11:608-61. <http://doi.org/dzq9s2>

36. Picano E, Vañó E, Rehani MM, Cuocolo A, Mont L, Bodi V, et al. The appropriate and justified use of medical radiation in cardiovascular imaging: a position document of the ESC Associations of Cardiovascular Imaging, Percutaneous Cardiovascular Interventions and Electrophysiology. *Eur Heart J* 2014;35:665-72. <http://doi.org/bkgq>

37. Picano E, Pellikka PA. Stress echo applications beyond coronary artery disease. *Eur Heart J* 2014;35:1033-40. <http://doi.org/bkgr>