

Longitudinal Strain Has No Ischemic Memory

El strain longitudinal no tiene memoria isquémica

JORGE LOWENSTEIN^{MTSAC}, NATALIO GASTALDELLO, PABLO MERLO^{MTSAC}, MARCELA GALELLO[†], MARÍA ROUSSE, VÍCTOR DARÚ^{MTSAC}

ABSTRACT

Background: Subendocardial longitudinal fibers are the most exposed during an ischemic event; therefore, longitudinal deformation is expected to be mainly affected. This would allow detecting subtle changes in myocardial motility visually unnoticed in the recovery period of a positive stress echo.

Objective: The aim of this study was to determine whether longitudinal strain by speckle tracking can express ischemic memory after the recovery of abnormal myocardial motility during a positive stress echo study.

Methods: Positive exercise stress echo studies without previous contractile disorders were included in the study. Resting longitudinal strain, at 30 seconds after supine exercise, and at 3 and 5 minutes of recovery was analyzed in an EchoPAC workstation.

Results: Twenty-one patients with positive stress echo were examined with a total of 101 ischemic segments. Mean longitudinal strain of ischemic segments at rest was $-22.3\% \pm 4.3\%$ and in the immediate post-exercise period (<30 seconds) it decreased to $16\% \pm 3.2\%$. At 3 minutes of recovery, ischemic segments had higher values than those obtained at rest: $-24.3\% \pm 5.1\%$ ($p=0.047$ vs. baseline). Ninety-eight percent of ischemic segments normalized the longitudinal strain after 3 minutes of completing the exercise.

Conclusion: Longitudinal strain alterations did not persist after recovery of visually analyzed segment motion abnormalities.

Key words: 2D Strain - Speckle Tracking - Ischemic Memory - Echocardiography, Stress

RESUMEN

Introducción: Las fibras longitudinales subendocárdicas son las más expuestas durante un evento isquémico, por lo que sería esperable que la deformación longitudinal sea la más afectada; esto permitiría en el período de recuperación de un eco estrés positivo detectar alteraciones sutiles de la motilidad miocárdica no reconocidas por el ojo.

Objetivo: Determinar si el strain longitudinal por speckle tracking puede expresar memoria isquémica luego de la recuperación de los trastornos de la motilidad durante un estudio de eco estrés positivo.

Material y métodos: Se incluyeron los estudios positivos de eco estrés con ejercicio sin trastornos contráctiles previos. Se analizó el strain longitudinal de reposo, a los 30 segundos posejercicio supino y a los 3 y 5 minutos de la recuperación en una estación de trabajo EchoPAC.

Resultados: Se examinaron 21 pacientes con eco estrés positivo con un total de 101 segmentos isquémicos. El promedio del strain longitudinal de los segmentos isquémicos en reposo fue de $-22,3\% \pm 4,3\%$; en el posejercicio inmediato (< 30 segundos) disminuyó a $-16\% \pm 3,2\%$. A los 3 minutos de la recuperación, los segmentos isquémicos presentaron valores mayores que los obtenidos en reposo: $-24,3\% \pm 5,1\%$ ($p = 0,047$ vs. baseline). El 98% de los segmentos isquémicos normalizaron el strain longitudinal a los 3 minutos de finalizado el ejercicio.

Conclusión: Las alteraciones del strain longitudinal no persistieron luego de la recuperación de los trastornos segmentarios de la motilidad analizados visualmente.

Palabras clave: Strain longitudinal 2D - Speckle tracking - Memoria isquémica - Ecocardiografía de estrés

Abbreviations

2D	Two-dimensional	SPECT	Single photon emission computed tomography
----	-----------------	-------	--------------------------------------------

REV ARGENT CARDIOL 2016;84:351-354. <http://dx.doi.org/10.7775/rac.v84.i4.9062>

SEE RELATED ARTICLE: REV ARGENT CARDIOL 2016;84:330-335. <http://dx.doi.org/10.7775/rac.v84.i4.8530>

REV ARGENT CARDIOL 2016;84:302-303. <http://dx.doi.org/10.7775/rac.v84.i4.9201>

Received: 04/21/2016 – Accepted: 06/15/2016

Address for reprints: Dr. Jorge Lowenstein – Investigaciones Médicas - Viamonte 1871 - (1056) CABA - e-mail: lowensteinjorge@hotmail.com

Investigaciones Médicas –Cardiac Diagnosis Unit. Buenos Aires, Argentina

^{MTSAC} Full Member of the Argentine Society of Cardiology

[†] To apply as Full Member of the Argentine Society of Cardiology

INTRODUCTION

Stress echo highlights the imbalance between oxygen supply and demand. Wall motion recovery requires perfusion restoration after transient myocardial ischemia.

SPECT studies with fatty acid analogues have revealed persistent, regional metabolic disorders as indicator of ischemic memory or metabolic stunning in the affected area. (1, 2)

Two-dimensional (2D) longitudinal strain assesses the behavior of sub-endocardial longitudinal fibers which are the ones most exposed during an ischemic event; therefore, longitudinal deformation is expected to be mainly affected and could detect subtle changes in myocardial motility visually unnoticed in the recovery period of a positive stress echo. (3)

If useful, this could be an early detection tool in patients with recent ischemic event who are asymptomatic at the time of consultation and in patients with ischemic response during a stress study in the recovery period when contractility disorders have already disappeared from the visual analysis.

This study was performed to determine whether longitudinal strain by speckle tracking is capable of expressing ischemic memory following recovery of motility disorders, during a positive stress echo study.

METHODS

Patients referred to our laboratory for an exercise stress echo study with positive result and no contractility abnormalities at rest were prospectively included between February and May, 2015.

Patients with left bundle branch block, absence of sinus rhythm, frequent ventricular extrasystoles, significant left ventricular hypertrophy, severe to mild left valve disease, history of prior revascularization and patients with impaired contractility and/or poor 2D image quality were excluded.

Regional and global longitudinal strain analysis was performed at a GE workstation with images obtained at rest, at 30 seconds post-supine exercise and at 3 and 5 minutes of recovery, acquired with single focus and at a frame rate of 50-80 frames per second.

The requisite to consider normalization of wall motion index was the recovery moment in which at a HR<100 beats/min the contractility disorders disappeared.

Demographic data, gender, age, cardiovascular risk factors, heart rate and baseline blood pressure (Table 1), wall motion index and longitudinal strain, discriminated for each of the 16 segments, and the average longitudinal strain of

all the segments and of the theoretical coronary territories were recorded.

Statistical analysis

The results for continuous variables are expressed as mean and standard deviation or median and interquartile range. The comparison between quantitative variables was performed using Student's t test, ANOVA followed by the Bonferroni test or nonparametric test as appropriate. Categorical variables were compared using the chi square test or Fisher's exact test. A repeated measures design was also performed to compare means at three different time points.

Ethical considerations

The study was evaluated and approved by an institutional Research Committee. An informed consent, authorized by a family member or responsible person, was required for each patient included in the study.

RESULTS

Twenty one patients with positive stress echo were examined with a total of 101 ischemic segments. Seventy-two per cent of ischemic segments corresponded to the theoretical territory of the left anterior descending artery. At 3-minute recovery, ischemic segments had higher values than those obtained at rest, [-24.3%±5.1% (p=0.047 vs. baseline longitudinal strain)] (Table 2).

Ninety-eight per cent of the evaluated ischemic segments showed normal longitudinal strain at 3 minutes of exercise conclusion (see Table 2).

As an example, Figure 1 shows the longitudinal strain of a patient in the three stages analyzed.

DISCUSSION

One of the new tools attempting to overcome the subjectivity of stress echo interpretation is 2D strain or deformation based on speckle tracking. (3)

The main advantages of longitudinal strain are its simple and rapid implementation and interpretation and, as it is not based on Doppler effect, it is independent of the scan angle; therefore, it may be applied to all myocardial segments and its results are validated by sonomicrometry and magnetic resonance tagging. (4, 5)

The main purpose of this study was to evaluate whether longitudinal strain alterations persisted for a few minutes after wall motion normalization in positive studies.

Results verified the prompt recovery of longitudinal strain after its impairment, so the main objective of finding with longitudinal strain a useful functional

Table 1. Patient baseline characteristics (total n=21)

Age, years	59.6 ± 9.4
Male gender, n (%)	15 (71)
Diabetes, n (%)	8 (38)
Hypertension, n (%)	13 (62)
Dyslipidemia, n (%)	15 (71)
Smoking, n (%)	3 (14)
Ex-smokers, n (%)	13 (62)

Table 2. Baseline global longitudinal deformation at rest, at peak stress and at 3-minute recovery

	Baseline	Peak stress	3-minute recovery
LD (%)	- 22.3 % ± 4.3	- 16.0 % ± 3.2	- 24.3 % ± 5.1

* p=0.047 between baseline and recovery
LD: Longitudinal deformation

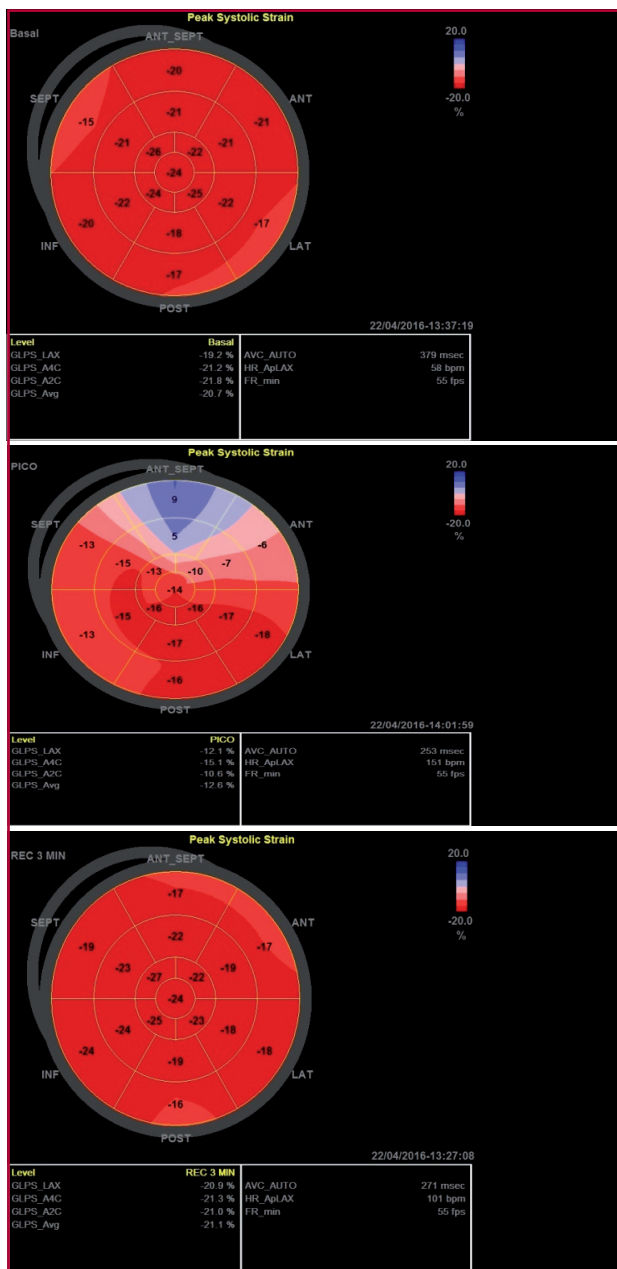


Fig. 1. Positive apical, anteroseptal, anterior and inferior stress echo with -20.7% longitudinal strain at rest (A), -12.6% at peak stress (B) and -21.1% at 3-minute recovery (C), in a 65-year-old patient, with coronary angiography confirming severe anterior descending artery and right coronary artery lesions.

window for the detection of ischemic memory was negative.

SPECT studies using fatty acid analogues showed regional metabolic abnormalities after a short period of pain at rest as an indicator of ischemic memory or metabolic stunning in the affected area. (1, 2)

The only experiences with longitudinal strain found in PubMed are experimental studies, confirming that, in dogs, after the ligation of a coronary artery and severe longitudinal strain deterioration, recovery occurs

immediately after flow restoration. The three works by the same Japanese group, however, show that there is a greater persistence of post-systolic contraction which can last up to 30 minutes (6-8). In our experience, 98 of the 101 ischemic segments normalized within 3 minutes after stress conclusion, with longitudinal strain values even higher than those of baseline, as a result of post ischemic flow (see Figure 1).

Probably the low persistence of abnormal segmental longitudinal deformation has depended on the short ischemic time, since, in our patients, the effort in supine position is immediately discontinued when wall motion abnormalities are detected in two contiguous segments.

According to experimental studies (6-8) the high energy expenditure during the initial period of diastole suggests that only the assessment of post-systolic contraction could provide more information than longitudinal strain regarding ischemic memory. (9)

Practical application

The isolated analysis of systolic longitudinal strain in the early recovery period of a positive stress echo, with no contractility residual changes, did not provide useful information.

These results allow better understanding of why longitudinal strain is unable to predict the result of a stress echo or the presence of significant coronary lesions, as demonstrated in a study published in this issue of the Journal. (10)

Limitations

This is a pilot study, with few patients, in whom only longitudinal strain was analyzed. Neither radial nor circumferential strain nor the different strain layers were considered. We are in a period of recruiting a greater number of studies with additional post-systolic deformation and strain rate information, which were not analyzed in this work.

CONCLUSIONS

Longitudinal strain did not present ischemic memory in the post stress recovery period with normalized contractility.

Conflicts of interest

Dr. Jorge Lowenstein has received medical fees for lectures on behalf of General Electric. The other authors have no conflicts of interest.

(See authors' conflicts of interest forms in the website/Supplementary material)

REFERENCES

1. Kawai Y, Tsukamoto E, Nozaki Y, Morita K, Sakurai M, Tamaki N. Significance of reduced uptake of iodinated fatty acid analogue for the evaluation of patients with acute chest pain. *J Am Coll Cardiol* 2001;38:1888-94. <http://doi.org/fwsref>
2. Dilsizian V, Bateman TM, Bergmann SR, Des Prez R, Magram MY, Goodbody AE, et al. Metabolic imaging with beta-methyl-p-[(123)I]-iodophenyl-pentadecanoic acid identifies ischemic memory after de-

- mand ischemia. *Circulation* 2005;112:2169-74. <http://doi.org/ff548t>
3. Moonen M, Lancellotti P, Zacharakis D, Pierard L. The value of 2D strain imaging during stress testing. *Echocardiography* 2009;26:307-14. <http://doi.org/cb5wd6>
4. Perk G, Kronzon I. Non-Doppler two dimensional strain imaging for evaluation of coronary artery disease. *Echocardiography* 2009;26:299-306. <http://doi.org/cxgh9z>
5. Götte MJ, Germans T, Rüssel IK, Zwanenburg JJ, Marcus JT, van Rossum AC, et al. Myocardial strain and torsion quantified by cardiovascular magnetic resonance tissue tagging: studies in normal and impaired left ventricular function. *J Am Coll Cardiol* 2006;48:2002-11. <http://doi.org/czr23q>
6. Asanuma T, Uranishi A, Masuda K, Ishikura F, Beppu S, Nakatani S. Assessment of myocardial ischemic memory using persistence of post-systolic thickening after recovery from ischemia. *JACC Cardio-vasc Imaging* 2009;2:1253-61. <http://doi.org/b9sdhg>
7. Asanuma T, Fukuta Y, Masuda K, Hioki A, Iwasaki M, Nakatani S. Assessment of myocardial ischemic memory using speckle tracking echocardiography. *JACC Cardiovasc Imaging* 2012;5:1-11. <http://doi.org/fxkkwp>
8. Sakurai D, Asanuma T, Masuda K, Hioki A, Nakatani S. Myocardial layer-specific analysis of ischemic memory using speckle tracking echocardiography. *Int J Cardiovasc Imaging* 2014;30:739-48. <http://doi.org/bkhz>
9. Belohlavek M. Post-systolic shortening: a functional window into ischemic memory? *JACC Cardiovasc Imaging* 2012;5:12-4. <http://doi.org/fx8fr5>
10. Gastaldello N, Merlo P, Amor M, Alasia D, Galello M, Rousse M et al. Longitudinal Strain at Rest Does not Predict Stress Echo Results. *Rev Argent Cardiol* 2016;84:302-3.