

# First implantation of HeartMate 3™ left ventricular assist device as destination therapy in Argentina. Review of the literature

*Primer implante exitoso de asistencia ventricular izquierda HeartMate 3™ como terapia de destino en Argentina. Revisión de la literatura*

ALEJANDRO M. BERTOLOTTI<sup>1</sup>, DANIELA M. RUBIRA<sup>1</sup>, MARÍA F. RENEDO<sup>1</sup>, ELIÁN F. GIORDANINO<sup>1</sup>, ALDANA S. AMERI<sup>1</sup>, ALEJANDRO E. CICOLINI<sup>2</sup>, LILIANA E. FAVALORO<sup>1</sup>, ROBERTO R. FAVALORO<sup>1,3</sup>, DANIEL O. ABSI<sup>1</sup>

## ABSTRACT

**Background:** We report the first successfully implantation of a left ventricular assist device as destination therapy using fully magnetically centrifugal continuous-flow device HeartMate 3™ (Abbott) in Argentina. The device was implanted in a 52-year-old female patient with left ventricular noncompaction with severe left ventricular dysfunction, pulmonary hypertension, advanced heart failure INTERMACS profile 3 and contraindication for heart transplantation due to high titers of preformed antibodies against the HLA system with crossmatch in Panel Reactive Antibody.

**Key words:** Heart Failure- Heart-Assist Devices - Ventricular Dysfunction, Left

## RESUMEN

Se presenta el primer implante exitoso de asistencia ventricular izquierda como terapia de destino mediante el dispositivo de flujo continuo centrífugo con levitación magnética intracorpóreo HeartMate 3™ (Abbott) en la Argentina. El dispositivo se implantó en una paciente de 52 años portadora de miocardio no compacto con disfunción ventricular izquierda grave, hipertensión pulmonar, insuficiencia cardíaca avanzada en estadio INTERMACS 3 y contraindicación para trasplante cardíaco debido a títulos elevados de anticuerpos preformados contra el sistema HLA en crossmatch contra panel.

**Palabras claves:** Insuficiencia cardíaca –Corazón auxiliar – Disfunción ventricular izquierda

## INTRODUCTION

Over the past decade, treatment of heart failure (HF) with reduced ejection fraction has experienced continued advances. (1,2) Nevertheless, some patients will progress to advanced stages of the disease and other therapeutic options should be considered. Heart transplantation (HTx) is still the treatment of choice in our environment. However, the increased number of HF patients (> 26 million worldwide), the shortage of donors (4,000 donors/year worldwide in average) and certain contraindications, generated the need to look for other alternatives. (3,4) Mechanical circulatory support devices (MCSDs) are a safe and efficient option in a broad spectrum of clinical situations. Since 2003, these devices have been used to provide circulatory support as permanent destination therapy when HTx cannot be considered. (5)

We report the first implantation of a HeartMate 3™ (HM3, Abbott Laboratories) left ventricular assist device (LVAD) as destination therapy in Argentina.

## CASE REPORT

The patient was a 52-year-old woman with a history of left ventricular noncompaction and severe left ventricular dysfunction. She did not present cardiovascular risk factors and had a history of two vaginal deliveries, mixed anxiety and depressive disorder (ICD-10 F41.2) followed-up by psychopathologist, and cardiac device-related infective endocarditis (cardiac resynchronization therapy device (CRTD)). The patient evolved with progression to functional class III-IV, hospitalizations for acute decompensated heart failure (ADHF) and decline on quality of life. In June 2019 she underwent evaluation for HTx: weight 46

REV ARGENT CARDIOL 2021;89:239-243. <http://dx.doi.org/10.7775/rac.v89.i3.20012>

Received: 11/14/2020 – Accepted: 02/14/2021

**Address for reprints:** Dr. Alejandro M. Bertolotti - Avenida Belgrano 1782 – CABA, Argentina - C1093AAS - Phone: +54 11 4378-1200 - E-mail: abertolotti@ffavaloro.org

<sup>1</sup> Heart Failure, Mechanical Circulatory Support and Heart Transplantation Division. Department of Intrathoracic Transplant

<sup>2</sup> Cardiovascular Intensive Care Unit

<sup>3</sup> Department of Cardiovascular Surgery

Hospital Universitario Fundación Favaloro. Buenos Aires, Argentina.

kg, height 1.68 m, body mass index 16.4 kg/m<sup>2</sup>, body surface area 1.5 m<sup>2</sup>.

On color-Doppler echocardiography the left ventricle was severely dilated, with eccentric hypertrophy and high degree of trabeculated myocardium (trabeculated to compact myocardium ratio >2:1). Left ventricular ejection fraction 18%. Global hypokinesia. Severe dilation of both atria. Mild right ventricular (RV) dilation (45 mm in 4-chamber view) with mild RV dysfunction (S-wave with TDI at the level of the tricuspid annulus 10 cm/s, fractional area change 0.33). Mild to moderate mitral regurgitation with mitral valve tenting. Mild to moderate tricuspid regurgitation (TR) with RV systolic pressure (SP) of 64 mmHg and dilated (23 mm) inferior vena cava (IVC) with absence of inspiratory collapse. Coronary angiography: absence of significant lesions in the coronary arteries.

Right heart catheterization under inotropic support with milrinone 0.5 mcg/kg/min showed the following data: heart rate: (HR) 78 bpm, mean blood pressure (MBP) 70 mmHg, pulmonary artery systolic pressure (PASP) 43 mmHg, pulmonary artery diastolic pressure (PADP) 19 mmHg, and mean pulmonary artery pressure (MPAP) 27 mmHg; pulmonary capillary wedge pressure (PCWP) 17 mmHg and right atrial pressure (RAP) 7 mmHg; cardiac output (CO) 3.2 L/min, cardiac index (CI) 2.1 L/m<sup>2</sup>, systemic vascular resistance (SVR) 1575 dyne.s.cm<sup>-5</sup>, and pulmonary vascular resistance (PVR) 280 dyne.s.cm<sup>-5</sup> (3.5 Wood Units), with transpulmonary pressure gradient (TPG) 10 mmHg. Serology tests for HIV, viral hepatitis B and C and Chagas' disease were negative.

The presence of preformed antibodies against the HLA system was detected: PRA (panel reactive antibody) Class I antibodies of 90% and Class II antibodies of 97%, complement-fixing antibodies detected by C1q assay with high immunofluorescence index (IMF). Desensitization therapy was initiated with intravenous immune globuline (IvIg) and rituximab (MabThera™). The PRA was repeated without significant changes. Due to the lack of response to desensitization therapy and considering that HTx is associated with high short- and mid-term morbidity and mortality, destination therapy with LVAD was decided. The patient evolved with progressive clinical impairment; multiple organ failure was controlled with maximal doses of inotropic agents, high doses of loop diuretics, hypertonic saline and sequential tubular blockade due to refractory congestion. Color-Doppler echocardiography showed RV dilation (basal diameter 53.5 mm) moderate to severe RV dysfunction (S-wave with TDI at the level of the tricuspid annulus 13 cm/s, fractional area change 0.20), and mild to moderate mitral regurgitation. Severe tricuspid regurgitation (TR) with maximal velocity 2.5 m/s, RVSP 40 mmHg, dilated (30 mm) IVC with absence of inspiratory collapse.

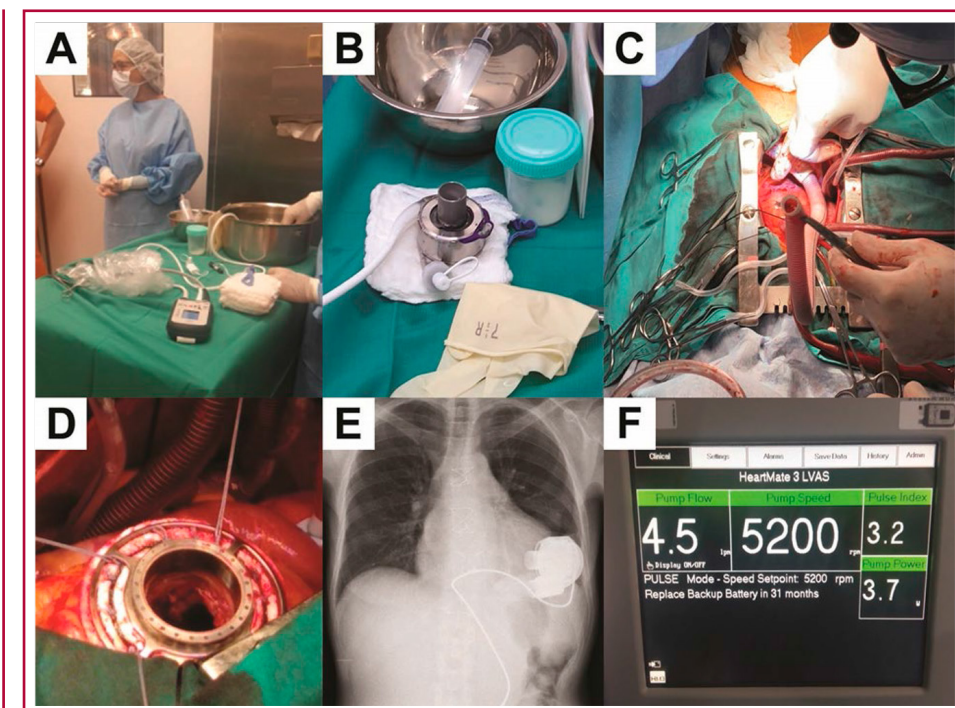
A new right heart catheterization was performed: HR 114 bpm, MBP 81 mmHg, PASP 42 mmHg, PADP 20 mmHg, MPAP 29 mmHg, PCWP 15 mmHg, RAP

12 mmHg; CO 4.24 L/min, CI 2.77 L/m<sup>2</sup>, SVR 1301 dyne.s.cm<sup>-5</sup>, PVR 266 dyne.s.cm<sup>-5</sup> (3.3 WU), TPG 10 mmHg. An intra-aortic balloon pump was implanted but had to be removed 72 hours later due to catheter-related infection and an image suggestive of intracavitary vegetation adhered to a cardiac device. The CRTD was explanted and intravenous antibiotic therapy was initiated. With negative cultures and after signing the informed consent form, we scheduled implantation of a LVAD as destination therapy.

On December 11, 2019, HeartMate 3 Left Ventricular Assist System (St. Jude Medical Inc., Pleasanton, California), a fully magnetically levitated centrifugal continuous-flow left ventricular assist device was implanted. This device includes Full MagLev Flow Technology designed to enhance hemocompatibility by minimizing shear force effects on blood components and by incorporating an optimized blood-biomaterial interface. The internal surfaces are textured with titanium microspheres to reduce thrombogenicity. The device consists of a fully levitated rotor with intrinsic pulsatility through a speed change every 2 seconds to reduce blood stasis and minimize the thrombogenic effect. The pump operates at rotor speed in the range of 3,000 to 9,000 rpm, and the maximum flow rate is 10 L/min. The pump motor receives power from a pair of 14V lithium-ion batteries or external AC power sources. A cable that is tunneled and externalized through the abdominal wall (modular cable or driveline) connects the pump power with the control system (driver) and the external batteries to transmit data and energy. Compared with HeartMate IITM (HM IITM), this device is designed for intrathoracic and intrapericardial placement, has longer power efficiency, the software is incorporated in the pump and blood flow is calculated according to the hematocrit.

The device was implanted through median sternotomy, with the heart beating, using temporary cardiopulmonary bypass and blood-sparing techniques. HM3™ consists of an inflow cannula that is introduced into the left ventricle through the apex which is sutured to a sewing ring in the epicardial surface of the apex of the LV and provides support for the pump. The myocardium inside the sewing ring is removed using a circular knife. Obstructing trabeculae are resected to achieve a free inflow into the pump. The cannula connected to the body of the pump is introduced and positioned within the pericardial space. The body of the pump continues with the outflow cannula, which is attached to a Dacron vascular graft that is anastomosed to the ascending aorta. The driveline is tunneled and exteriorized through the abdominal wall and connected to the control system. De Vega anuloplasty was performed since the patients presented severe RV dysfunction and tricuspid regurgitation, with intermediate to high RV failure risk scores. Once the outflow graft and pump were de-aired, cardiopulmonary bypass flow was decreased, and the pump was turned on at 3000 rpm. Ramped speed tests were per-

**Fig. 1.** Implant and programming of HM3 LVAD as destination therapy



**A.** Operating table showing the control system and driveline of the HM3™ device (Abbott) and the basin to immerse the pump in sterile saline prior to start-up. **B.** Left ventricular assist device or fully magnetically levitated pump HM3™ (Abbott) before implantation. This design allows unidirectional flow between the inflow cannula and outflow cannula, minimizing shear force effects through a magnetic field with highly efficient energy. **C.** Dacron graft connecting the outflow cannula to the ascending thoracic aorta. **D.** The sewing ring sutured in the left ventricular apex will be connected to the inflow cannula of the pump. **E.** Chest-X ray after implantation showing the different components of the device. **F.** Initial programming of long-term left ventricular assist device.

formed to determine adequate speed setting. Hemodynamic monitoring was performed with pulmonary artery catheter and central venous oxygen saturation (Figure 1). Inotropic support and infusion of nitric oxide for RV support were continued for the first 48 h, without the need for mechanical support. The patient was weaned from mechanical ventilation at 72 h, remained in the intermediate care unit for 16 days, and was discharged from hospital 30 days after implantation. Anticoagulation and antiplatelet therapy were established according to the indications of the manufacturer and hematologists, and to evidence-based medical recommendations. On discharge, the patient was in NYHA FC II, receiving optimal medical treatment for LV systolic dysfunction according to international guidelines. Treatment with sildenafil was continued, with a progressive decrease in the dose. Cardiac rehabilitation and supervised nutrition program were indicated.

During hospital stay, an experienced surgeon and nurse provided by the manufacturer were in charge of training and counseling the patient, her family and the medical team for a total of 20 hours about battery replacement, care of the equipment, proper sterile dressing changes at the driveline exit site and management of emergency situations. Before discharge, the patient was authorized to leave hospital for short

periods of time under medical supervision to confirm her level of confidence and comfort with the system. The patient and her family demonstrated full autonomy and safety. A home visit was made to supervise the electrical installations, assess the general safety conditions of the house, ensure the safety of electricity supply and survey alternative charging sites in the community. During training, absolute contraindications for immersion in water and for undergoing nuclear magnetic resonance imaging tests were emphasized. She was instructed to use a special kit to protect the equipment from water during daily hygiene. Emergency department physicians were trained for the initial management of the possible complications.

Since she has been discharged, regular follow-up visits are performed to evaluate the presence of HF and possible bleeding, check for alarms or alerts, verify pulsatility index, amperage, revolutions per minute, cardiac output, and detect suction events. Follow-up visits include coagulation tests, examination of the exit site of the driveline to rule out associated infection; determination of mean blood pressure by Doppler ultrasound; electrocardiogram, laboratory tests with lactate dehydrogenase levels and Doppler echocardiography to optimize device parameters. Six months after implantation, the patient was asymptomatic and self-sufficient in daily life activities. She

was involved in a cardiovascular rehabilitation program. Her nutritional profile and mood improved significantly, and she had adequate levels of anticoagulation. A 6-minute walk test (6MWT) with pulse oximetry while breathing room air resulted in 480 meters walked, with a score of 0 in the Borg scale.

## DISCUSSION

In the management of patients with advanced HF refractory to medical treatment and electrophysiological devices (1-3), HTx remains the most effective treatment for improving both quality of life and long-term survival (mean conditional survival 14.8 years). (6) Nevertheless, other options must be offered when HTx cannot be indicated or its latency requires providing the patient with a period of stability. (4)

The development of MCSDs was technologically sophisticated, and they are now positioned as a safe tool, capable of providing hemodynamic support that allows time to improve the clinical status as a bridge to HTx or bridge to decision or candidacy, in cases of potentially amendable limitations; temporary support as a bridge to recovery in reversible conditions, or as destination therapy when there are contraindications for HTx. (5-8) Deciding the appropriate timing for implantation is a crucial step. INTERMACS (Interagency Registry for Mechanically Assisted Circulatory Support) profiling, supported by the National Heart-Lung and Blood Institute (NHLBI), which has been analyzing patients implanted with FDA (Food and Drug Administration) approved devices since June 23, 2006, provides better identification of the associated risks according to the time of implantation. (9,10) Such devices can provide short-, medium- and long-term support in patients with acute and chronic heart failure.

Older pulsatile devices were used for short-term support, but in 1998 the FDA approved them as a bridge to HTx. Technological advances determined that these devices are a safe alternative for long-term support. (7) In 2001, the REMATCH (Randomized Evaluation of Mechanical Assistance for the Treatment of Congestive Heart Failure) trial demonstrated that mortality in non-transplantable patients treated with medical treatment was higher compared with patients with pulsatile LVADs; in these patients, mortality decreased by 48%. Although complications as thromboembolism, bleeding and infections limited the time of use, this clinical trial supports LVADs as destination therapy. (11) The INTrEPID (Investigation of Nontransplant-Eligible Patients Who Are Inotrope Dependent) trial demonstrated that LVAD-treated patients with Novacor® device had superior survival rates at 6 months (46% vs. 22%) and at 12 months (27% vs. 11%) compared with optimal medical treatment in non-transplantable patients with severe end-stage HF and severely reduced left ventricular ejection fraction. (12)

Continuous-flow LVADs, including axial-flow and

centrifugal-flow pumps, are smaller and easier to implant. Since 2007, their usefulness have been demonstrated in clinical studies, initially against a control group. Later, in 2009, they proved to be superior to pulsatile-flow devices. (13) These pumps led to the current generation of centrifugal continuous-flow LVADs, which use a single fully magnetically levitated rotor. (14,15)

The LVAD HM3™ is intended to provide hemodynamic support in patients with HF as a bridge to HTx or as destination therapy in patients with severe left ventricular dysfunction. Right ventricular failure risk scores and the patient's prognosis must be estimated before the univentricular device is implanted in each case. (16) Intolerance or allergy to anticoagulants are contraindications for the implant.

Krabatsch et al. demonstrated FC improvement from IIIb/IV to I/II 6 months after implantation in more than 78% of patients, with sustained improvement in 79% along 2 years ( $p < 0.0001$ ), confirmed by 6MWT (mean distance walked at baseline 154 m, which increased to 308 m 2 years after implantation,  $p < 0.0001$ ). (17)

The MOMENTUM 3 trial published in 2018 (Abbott) is a nonblinded, randomized study that sought to demonstrate non-inferiority by comparing the axial-flow HM II™ with the centrifugal-flow HM3™ after 2-year follow-up. The primary end point was a composite of survival at 2 years free of disabling stroke (with disabling stroke according to modified Rankin scale) or survival free of reoperation to replace or remove a malfunctioning device. A total of 366 patients were randomly assigned in a 1:1 ratio to receive either the HM3™ ( $n = 190$ ) or the HM II™ ( $n = 176$ ), and were evaluated at 1 month, at 3 months, and then every 6 months until 2 years of follow-up. At 6 months, only 3 patients (1.6%) in the group HM3™ underwent pump replacement (1 for a driveline communication fault causing electrical failure, 1 because of a driveline infection, and 1 because of an obstructive outflow-graft twist), with absence of pump thrombosis compared with 10% in the group HM II™. The primary end point occurred in 79.5% of patients in the HM3 group, as compared with 60.2% in the HM II™ group, achieving noninferiority. Survival free of disabling stroke was observed in 89.1% of the patients with HM3 and in 76.3% of those with HM II™, but this difference was not statistically significant. (18) Despite there were no significant differences in the rate of gastrointestinal bleeding, the centrifugal-flow pump had less tendency to cause von Willebrand factor deficiency and arteriovenous malformations than the axial-flow pump. (19-21) The results with HM3™ with respect to 2-year event-free survival are comparable to those obtained with HTx in many regions worldwide. (22)

It should be emphasized that proper management of the device is essential to ensure therapy success in the long term. Therefore, the patient and his/her fam-

ily require sufficient time to acquire the knowledge and skills required for daily self-care of the device.

### CONCLUSIONS

We reported the first successfully implantation of an LVAD as destination therapy in the country in a patient with HF and contraindication to HTx.

Heart failure will continue to be managed by different methods: genetic, replacement and mechanical support. Left ventricular assist devices have proven to provide efficient support in the short and long term as a bridge to HTx and destination therapy. Device design and operation will gradually improve, and they will undoubtedly become more efficient, more durable and less expensive, and their use will result in fewer complications. This therapy has great challenges ahead, and at the same time it is no longer exceptional.

### Conflicts of interest

None declared.

(See authors' conflicts of interest forms on the website/ Supplementary material)

### Sources of funding:

This study did not receive any grant or financial support.

### REFERENCES

- Greene SJ, Butler J, Albert NM, DeVore AD, Sharma PP, Duffy CI, et al. Medical therapy for heart failure with reduced ejection fraction: the CHAMP-HF registry. *J Am Coll Cardiol* 2018;72:351-66. <https://doi.org/10.1016/j.jacc.2018.04.070>.
- Brunner-La Rocca HP, Linssen GC, Smeele FJ, van Drimmelen AA, Schaafsma HJ, Westendorp PH, et al. Contemporary drug treatment of chronic heart failure with reduced ejection fraction: the CHECK-HF registry. *JACC Heart Fail* 2019;7:13-21. <https://doi.org/10.1016/j.jchf.2018.10.010>.
- Nauman D, Walker TL, Dutton D, Burgess D. Care processes and clinical outcomes of continuous outpatient support with inotropes (COSI) in patients with refractory endstage heart failure. *J Card Fail* 2003;9:180-7. <https://doi.org/10.1054/jcaf.2003.24>.
- Prinzing A, Herold U, Berkefeld A, et al. Left ventricular assist devices current state and perspectives. *J Thorac Dis* 2016;8:E660-6. <https://doi.org/10.21037/jtd.2016.07.13>.
- Deng MC, Edwards LB, Hertz MI, Rowe AW, Keck BM, Kormos R, et al. Mechanical circulatory support device database of the International Society for Heart and Lung Transplantation: third annual report - 2005. *J Heart Lung Transplant* 2005;24:1182-7. <https://doi.org/10.1016/j.healun.2005.07.002>.
- Khush KK, Cherikh WS, Chambers DC, Harhay MO, Hayes D Jr, Hsich E, et al. The International Thoracic Organ Transplant Registry of the International Society for Heart and Lung Transplantation: Thirty-sixth adult heart transplantation report - 2019; focus theme: Donor and recipient size match. *J Heart Lung Transplant* 2019;38:1056-66. [doi:10.1016/j.healun.2019.08.004](https://doi.org/10.1016/j.healun.2019.08.004)
- Stewart GC, Givertz MM. Mechanical circulatory support for advanced heart failure: patients and technology in evolution. *Circulation* 2012;125:1304-15. <https://doi.org/10.1161/CIRCULATIONAHA.111.060830>
- Slaughter MS, Singh R. The Role of Ventricular Assist Devices in Advanced Heart Failure. *Rev Esp Cardiol*. 2012; 65:982-985. <https://doi.org/10.1016/j.recesp.2012.02.030>
- Stewart GC, Kittleston MM, Patel PC, Cowger JA, Patel CB, Moun-tis MM,, et al. INTERMACS (Interagency Registry for Mechanically Assisted Circulatory Support) Profiling Identifies Ambulatory Patients at High Risk on Medical Therapy After Hospitalizations for Heart Failure. *Circulation Heart Fail* 2016;9:1-9. <https://doi.org/10.1161/CIRCHEARTFAILURE.116.003032>.
- Imamura T, Kinugawa K. Indication of Ventricular Assist Device Therapy in Patients with INTERMACS Profile 4-7. *Ann Thorac Cardiovasc Surg* 2016; 22:271-4. <https://doi.org/10.5761/atcs.ed.16-00119>
- Rose EA, Gelijns AC, Moskowitz AJ, Sollano JA, Williams DL, Tierney AR, et al. Randomized Evaluation of Mechanical Assistance for the Treatment of Congestive Heart Failure (REMATCH) Study Group. Long-term mechanical left ventricular assistance for end-stage heart failure. *N Engl J Med*. 2001;345:1435-43. [https://doi.org/10.1016/s0003-4975\(99\)00042-9](https://doi.org/10.1016/s0003-4975(99)00042-9).
- Rogers JG, Butler J, Lansman SL, Gass A, Portner PM, Pasque MK, et al. Chronic Mechanical Circulatory Support for Inotrope-Dependent Heart Failure Patients Who Are Not Transplant Candidates. Results of the INTRaEPID Trial. *J Am Coll Cardiol* 2007;74:1-7. <https://doi.org/10.1016/j.jacc.2007.03.063>.
- Slaughter MS, Rogers JG, Milano CA, Russell SD, Conte JV, Feldman D, et al. Advanced heart failure treated with continuous-flow left ventricular assist device. *New Engl J Med* 2009;361:2241-51. <https://doi.org/10.1056/NEJMoa0909938>.
- Netuka I, Sood P, Pya Y, Zimpfer D, Krabatsch T, Garbade J, et al. Fully Magnetically Levitated Left Ventricular Assist System for Treating Advanced HFA Multicenter Study. *J Am Coll Cardiol* 2015;66:2579-89. <https://doi.org/10.1016/j.jacc.2015.09.083>.
- Mehra MR, Naka Y, Uriel N, Goldstein DJ, Cleveland JC Jr, Colombo PC, et al. A Fully magnetically levitated circulatory pump for advanced heart failure. *N Engl J Med* 2017;376:440-50. <https://doi.org/10.1056/NEJMoa1610426>
- Matthews JC, Koelling TM, Pagani FD, Aaronson KD. The Right Ventricular Failure Risk Score: A Pre-Operative Tool for Assessing the Risk of Right Ventricular Failure in Left Ventricular Assist Device Candidates. *J Am Coll Cardiol* 2008;51:2163-72. <https://doi.org/10.1016/j.jacc.2008.03.009>.
- Krabatsch T, Netuka I, Schmitto JD, Zimpfer D, Garbade J, Rao V, et al. Heartmate 3 fully magnetically levitated left ventricular assist device for the treatment of advanced heart failure—1 year results from the Ce mark trial. *J Cardiothorac Surg* 2017;12:23. [doi:10.1186/s13019-017-0587-3](https://doi.org/10.1186/s13019-017-0587-3).
- Mehra MR, Goldstein DJ, Uriel N, Cleveland JC Jr, Yuzefpolskaya M, Salerno C, et al. MOMENTUM 3 Investigators. Two-year outcomes with a magnetically levitated cardiac pump in heart failure. *N Engl J Med* 2018;378:1386-95. <https://doi.org/10.1056/NEJMoa1800866>.
- Klovaite J, Gustafsson F, Mortensen SA, Sander K, Nielsen LB. Severely impaired von Willebrand factor-dependent platelet aggregation in patients with a continuous-flow left ventricular assist device (HeartMate II). *J Am Coll Cardiol* 2009; 53:2162-7. <https://doi.org/10.1016/j.jacc.2009.02.048>.
- Demirozu ZT, Radovancevic R, LF, Gregoric ID, Letsou GV, Kar B, Bogaev RC, et al. Arteriovenous malformation and gastrointestinal bleeding in patients with the HeartMate II left ventricular assist device. *J Heart Lung Transplant*. 2011;30:849-53. <https://doi.org/10.1016/j.healun.2011.03.008>.
- Uriel N, Colombo PC, Cleveland JC, Long JW, Salerno C, Goldstein DJ, et al. Hemocompatibility-related outcomes in the MOMENTUM 3 trial at 6 months: a randomized controlled study of a fully magnetically levitated pump in advanced heart failure. *Circulation* 2017;135:2003-12. <https://doi.org/10.1161/CIRCULATIONAHA.117.028303>
- Theochari CA, Michalopoulos G, Oikonomou EK, Giannopoulos S, Doulamis IP, Alvarez Villela M, et al. Heart transplantation versus left ventricular assist devices as destination therapy or bridge to transplantation for 1-year mortality: a systematic review and meta-analysis. *Ann Cardiothorac Surg* 2018;7:3-11. <https://doi.org/10.21037/acs.2017.09.18>