

# First Perceval S™ Sutureless Aortic Valve Prosthesis Implantations in Argentina

*Primeros implantes de la válvula sin sutura Perceval S® en Argentina*

RAÚL A. BORRACCI<sup>1</sup>, WALTER RODRÍGUEZ<sup>2</sup>, MARCELO BENÍTEZ<sup>3</sup>, FÉLIX RAMÍREZ<sup>1</sup>, MATÍAS RÍOS<sup>2</sup>, MAURO GIACOMINI<sup>3</sup>

## ABSTRACT

Aortic valve replacement with sutureless prostheses is an innovative alternative for the treatment of aortic stenosis in the elderly and in high-risk patients. Although the world experience with these prostheses has been going on for several years, only recently, the Perceval S™ model, consisting of a self-expanding sutureless prosthesis made of bovine pericardium and mounted on a nitinol stent, has begun to be commercialized in Argentina. In this study, we present the first three cases of aortic valve replacement with Perceval bioprostheses performed in Argentina. The sutureless technique is a promising alternative for surgical aortic valve replacement with a bioprosthesis, and may possibly compete with intravascular therapy in high-risk patients.

**Key words:** Aortic Valve/Surgery -Sutureless Surgical Procedures - Treatment Outcome

## RESUMEN

El reemplazo valvular aórtico con prótesis sin sutura es una alternativa innovadora para el tratamiento de la estenosis aórtica en los ancianos y en los pacientes de alto riesgo. Aunque la experiencia mundial con estas prótesis lleva ya varios años, solo recientemente comenzó a comercializarse en Argentina el modelo Perceval S®. Se trata de una prótesis autoexpandible sin sutura hecha de pericardio bovino y montada en un stent de nitinol. En este estudio se presentan los primeros tres casos de reemplazo valvular aórtico con la bioprótesis Perceval realizados en Argentina. La técnica sin sutura es una alternativa prometedora para el reemplazo valvular aórtico quirúrgico con una bioprótesis, y, posiblemente, pueda competir con la terapéutica intravascular en los pacientes de alto riesgo.

**Palabras clave:** Válvula aórtica/cirugía - Procedimientos quirúrgicos sin sutura - Resultado del tratamiento

## INTRODUCTION

Aortic valve replacement with sutureless prostheses is an innovative alternative for the treatment of aortic stenosis in the elderly and in high-risk patients, particularly in those with porcelain aorta or in reoperations of severely calcified homografts, in which adequate suturing for valve prosthesis implantation is difficult. (1-6) Although the experience with sutureless prostheses has been going on worldwide for several years, only recently has the Perceval S™ model (Sorin Group, Saluggia) been marketed in Argentina. It consists of a self-expanding bovine pericardial bioprosthesis mounted on a nitinol stent. The main characteristic of sutureless aortic valve implantation is the ease and speed of insertion after resecting the native valve under cardiopulmonary bypass. Therefore, cross-clamping and myocardial ischemic times can be

significantly shorter, especially in combined surgeries. (7) Thus, these new devices are able to compete with transcatheter aortic valve implantation (TAVI) in moderate- and high-risk patients. In a comparative study between Perceval and TAVI based on propensity score, the sutureless prosthesis showed better 36-month survival rate (97.5% vs. 84.8%,  $p=0.001$ ). (8) The purpose of this study was to present the first experience of aortic valve replacement with the sutureless Perceval S™ prosthesis in Argentina.

## METHODS

Three clinical cases of patients with Perceval S™ valve implanted between August 2017 and February 2018 are reported. These were the first implants of this sutureless aortic valve prosthesis carried out in Argentina by three different groups of surgeons in different surgical services. Since this

REV ARGENT CARDIOL 2018;86:266-270. <http://dx.doi.org/10.7775/rac.v86.i4.13376>

Received: 03-26-2018 – Accepted: 04-11-2018

<sup>1</sup> Clínica y Maternidad Suizo Argentina, Buenos Aires, Argentina

<sup>2</sup> Sanatorio Finochietto, Buenos Aires, Argentina

<sup>3</sup> Clínica Pueyrredón. Mar del Plata, Buenos Aires, Argentina

is a technical innovation, the clinical presentation, the selection process and choice of the new valve, the operative strategy, and the immediate and mid-term surgical outcome are reported for each case. It should be pointed out that these are the first consecutive implantations in the country, and that there were no other implants with unfavorable course or death, discarded and not included in this presentation. In all patients, the implantation technique under extracorporeal circulation consisted of high transverse aortotomy, resection of the diseased native valve, valve annulus diameter measurement and mounting of the collapsed prosthesis on the “holder”, placement and deployment of the prosthesis, balloon dilation, hydraulic leakage test and final aortorrhaphy. (Figure 1).

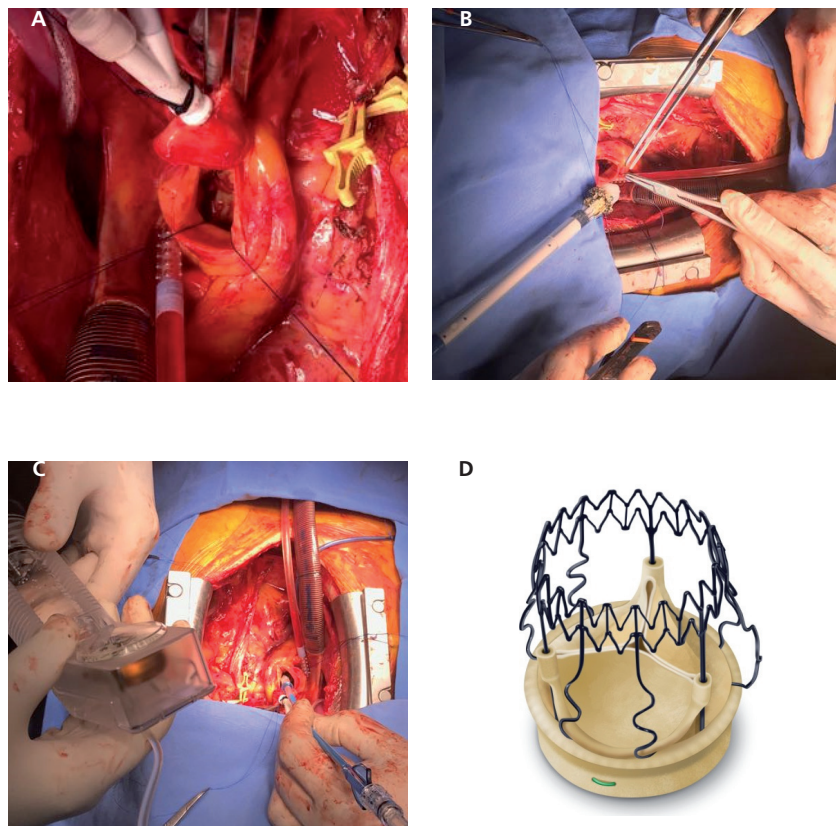
## RESULTS

Table 1 summarizes the baseline and operative characteristics of each patient.

**Patient 1.** A 75-year-old hypertensive and diabetic female patient, diagnosed with severe symptomatic aortic stenosis due to functional class-II dyspnea, was indicated an elective aortic valve replacement. The computed tomography angiography revealed moderate annular calcification, and the coronary angiography showed mild-to-moderate lesions in the anterior descending artery and its diagonal branch. Table 1 shows the rest of the perioperative characteristics. In August 2017, a Perceval valve was implanted under extracorporeal circulation. In the intraoperative

control with transesophageal echocardiography, the prosthetic valve was correctly positioned, with normal functioning, without paravalvular regurgitation and with a mean transvalvular gradient of 10 mmHg. Twelve hours after surgery, the patient presented with low cardiac output and vasoplegia, requiring prolonged mechanical ventilation, and progressed to early pneumonia caused by *Klebsiella pneumoniae*. Response to antibiotic therapy was effective, and the patient made good progress. Ambulatory transthoracic echocardiography performed 60 days after revealed normal prosthetic valve function.

**Patient 2.** An 86-year-old female patient with severe symptomatic aortic stenosis, progressive dyspnea and syncope, presented with functional class II-III at consultation. The patient had a history of pelvic non-Hodgkin’s lymphoma with dissection of bilateral pelvic-inguinal lymph node performed several years earlier, causing elephantiasis in both lower limbs which severely limited her movements. She was rejected for conventional surgery by three different institutions due to this condition, and her medical coverage understood that she did not meet the risk criteria to undergo TAVI. An aortic valve replacement with sutureless Perceval S™ prosthesis was proposed. The intervention was uneventful, replacing the native valve with a size M prosthesis (equivalent to a conventional 21/23 size prosthesis), with cross-clamping



**Fig. 1.** A. High aortotomy and complete resection of the calcified valve; B. Collapsed valve prosthesis at the end of the holder; C. Balloon inflation after self-deployment of the valve; D. Self-expanding sutureless Perceval S™ valve.

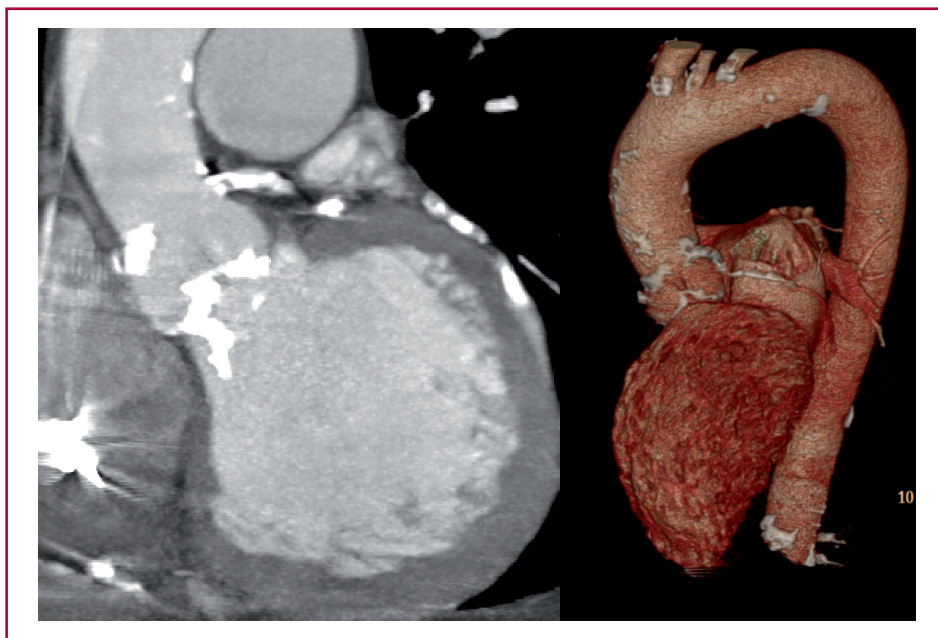
**Table 1.** Summary of the baseline and operative characteristics of each patient.

Variables	Patient 1	Patient 2	Patient 3
Age	74 years	86 years	87 years
Sex	female	female	male
Body mass index	35.1	36.2	24.2
Hypertension	yes	yes	yes
Diabetes	type II	no	type II
Heart failure	no	yes	yes
Ejection fraction	57%	51%	25%
Creatinine clearance (Cockcroft-Gault)	39 ml/min	45 ml/min	27 ml/min
EuroSCORE II	3.0%	2.95%	11.7%
Permanent (dual-chamber) pacemaker	no	no	yes
Diagnosis:			
Aortic valve stenosis	pure	pure	pure
Associated coronary heart disease	no	no	yes
Aortic and valve measurements:			
Aortic valve area	0.80 cm <sup>2</sup>	0.70 cm <sup>2</sup>	0.35 cm <sup>2</sup>
Sinotubular junction diameter	27.4 mm.	23.5 mm.	28.9 mm.
Aortic annulus diameter	21.2 mm.	21.4 mm.	25.2 mm.
Sinotubular junction/Aortic annulus ratio	1.29	1.09	1.15
Distance from aortic annulus to sinotubular junction	19.0mm	19.8 mm	20.5 mm
Valve implantation:			
Cross-clamping time	40 min	37/29 min	35 min
Implanted valve size	large	medium	medium
Simultaneous mammary-coronary artery bypass	no	no	off-pump
Residual valve regurgitation	none	none	none

time of 37 minutes (about 40% less than our average). According to the assisting expert's evaluation, the prosthetic valve had been correctly positioned. However, the transesophageal echocardiography performed before weaning from cardiopulmonary bypass showed a severe periprosthetic leak. This forced us to perform a new cross-clamping and reopening of the aorta. The revision showed that the prosthetic valve annulus was folded into the lumen, generating the space for periprosthetic regurgitation. The prosthesis was removed without complications, and was reimplemented, requiring a cross-clamping time of 29 minutes. No regurgitation was evidenced on the new echocardiography, and the patient was weaned from cardiopulmonary bypass without inotropic agents. It should be highlighted that the prosthetic valve can be removed and reimplemented without any problems. Despite the patient's large body surface area (1.95 m<sup>2</sup>), the "M" prosthesis did not generate significant gradients. The patient made a satisfactory recovery and was discharged on the 7th postoperative day without major complications. Four months after surgery, the patient did not experience dyspnea or other signs or symptoms of heart failure.

**Patient 3.** This is the case of an 87-year-old male patient with history of heart failure associated with

aortic valve stenosis, in whom surgery was contraindicated 4 years earlier due to his frailty. In addition, the patient presented with multiple comorbidities, summarized in Table 1. On admission, the patient was in functional class III due to dyspnea and recent onset angina, relieved with nitrites. Severe low-gradient aortic stenosis, increasing with the stress test, and an ejection fraction of 25% were confirmed. The patient presented a severely calcified valve, aortic root and left ventricular outflow tract associated with multiple vessel coronary artery disease, difficult to treat by transcatheter valve implantation and angioplasty (Figure 2). A combined surgical treatment of coronary artery bypass grafting and aortic valve replacement was decided. Given the severe calcification of the aortic annulus, which could hamper suturing a biological valve prosthesis, it was decided to use a sutureless Perceval S™ prosthesis. In order to shorten the time for extracorporeal circulation, an off-pump mammary artery bypass to the anterior descending artery was performed, followed by valve implantation under cardiopulmonary bypass. Hydraulic leakage test under direct vision and intraoperative transesophageal echocardiography showed no immediate valvular or paravalvular regurgitation. In the postoperative course, the patient was extubated within 6 hours and



**Fig. 2.** Computed tomography scan and computed tomography angiography images of one of the patients, showing severe calcification of the aortic valve and left ventricular outflow tract, diffuse calcifications of the ascending aorta, aortic arch, and coronary arteries, and left ventricular enlargement.

coursed the first week without complications. The patient was already on ambulatory status in his room when he suffered sudden death, responding to cardiopulmonary resuscitation. Once normal functioning of the coronary bypass and valve prosthesis was checked with a coronary angiography, implantation of a cardioverter defibrillator was programmed, but the patient died 15 days later.

## DISCUSSION

The self-expanding Perceval aortic valve prosthesis was designed to simplify surgical replacement, since it does not require the use of sutures for implantation. Some of the advantages of the Perceval valve are similar to those of traditional surgery: direct vision of valve removal and implantation, and annulus decalcification, reducing the chances of neurological events or paravalvular leaks, as it still occurs with TAVI. Worldwide experience with this sutureless valve is wide, although only recently it has been authorized for use in Argentina, at a cost between 2 and 4 times lower than that of TAVI.

Three systematic reviews and a meta-analysis of up to 14 observational studies involving 2,505 patients demonstrated shorter implantation times; mortality rates of 0 to 4.9% at 30 days, 0 to 14% at 1 year and 14.5 to 28.7% at 5 years; an incidence of stroke between 0 and 3%; need for permanent pacemaker between 0 and 17%; and paravalvular leak between 0 and 8.6%. (9-11) The largest European multicenter experience with the sutureless implant, which included more than 700 patients in 2016, showed very good clinical and hemodynamic results that remain stable in the 5-year follow-up. (12) Even in the older patient series, which included 40% of octogenarians, both immediate and remote mortality were very low, with no episodes of prosthetic migration, structural deteriora-

tion, or valve thrombosis at follow-up. Recently, the first early structural failure of this prosthesis (two years after implantation), (13) and a case of migration of the device detected 15 months after implantation have been reported. (14)

The possibility of replacing traditional bioprostheses with sutureless valves has recently been addressed, and a randomized controlled trial is currently underway to compare the results between regular prostheses and Perceval sutureless valves (PERSIST-AVR Clinical Trial, ClinicalTrials.gov NCT02673697). A meta-analysis of 6 comparative studies between the Perceval sutureless valve and a conventional bioprosthesis, including 1,400 patients, showed a significant reduction in cross-clamping time and less renal failure with the sutureless valve; also, a greater need for permanent pacemakers (7.9%) and equal in-hospital and one-year mortality. (15)

In conclusion, this study presented the first three cases of aortic valve replacement with the sutureless self-expanding Perceval S™ bioprosthesis performed in Argentina. The sutureless technique is a promising alternative for bioprosthetic aortic valve replacement, and may compete with intravascular therapy in high-risk patients.

## Conflicts of interest

None declared. (See authors' conflicts of interest forms on the website/Supplementary material).

## REFERENCES

1. Santarpino G, Pfeiffer S, Fischlein T. Perceval sutureless approach in a patient with porcelain aorta unsuitable for transcatheter aortic valve implantation. *Int J Cardiol* 2012;155:168-70. <http://doi.org/cr6x47>
2. Stoker T, Mashhour A, Easo J, Kronberg K, Ennker J, Weymann A. Novel Treatment of a Degenerated Bioroot With the Use of the

Sutureless Valve Technique. *Ann Thorac Surg* 2018;105:e213-e214. <http://doi.org/gdf7f5>

3. Baikoussis NG, Dedeilias P, Prappa E, Argiriou M. The Perceval S aortic valve implantation in patients with porcelain aorta; is this ideal option? *Ann Card Anaesth* 2017; 20(Supplement):S70-S72. <http://doi.org/cq4n>

4. Lio A, Scafuri A, Nicolò F, Chiariello L. Valve Replacement with a Sutureless Aortic Prosthesis in a Patient with Concomitant Mitral Valve Disease and Severe Aortic Root Calcification. *Tex Heart Inst J* 2016;43:186-8. <http://doi.org/f8jhck>

5. Folliguet TA, Laborde F. Sutureless Perceval aortic valve replacement in aortic homograft. *Ann Thorac Surg* 2013;96:1866-8. <http://doi.org/f5gbhz>

6. Villa E, Messina A, Cirillo M, Brunelli F, Mhagna Z, Dalla, et al. Perceval sutureless valve in freestyle root: new surgical valve-in-valve therapy. *Ann Thorac Surg* 2013;96: e155-7. <http://doi.org/cq4p>

7. Davies RA, Bandara TD, Perera NK, Orr Y. Do rapid deployment aortic valves improve outcomes compared with surgical aortic valve replacement? *Interact Cardiovasc Thorac Surg* 2016;23:814-20. <http://doi.org/cq4q>

8. Santarpino G, Vogt F, Pfeiffer S, Dell'Aquila AM, Jess J, Cuomo F, et al. Sutureless versus Transfemoral Transcatheter Aortic Valve Implant: A Propensity Score Matching Study. *J Heart Valve Dis* 2017;26:255-61.

9. Phan K, Tsai YC, Niranjana N, Bouchard D, Carrel TP, Dapunt

OE, et al. Sutureless aortic valve replacement: a systematic review and meta-analysis. *Ann Cardiothorac Surg* 2015;4:100-11. <http://doi.org/cq4s>

10. Takagi H, Umemoto T. A Meta-Analysis of Sutureless or Rapid-Deployment Aortic Valve Replacement. *Thorac Cardiovasc Surg* 2016;64:400-9. <http://doi.org/cq4t>

11. Sian K, Li S, Selvakumar D, Mejia R. Early results of the Sorin(®) Perceval S sutureless valve: systematic review and meta-analysis. *J Thorac Dis* 2017;9:711-24. <http://doi.org/cq4v>

12. Shrestha M, Fischlein T, Meuris B, Flameng W, Carrel T, Madonna F, et al. European multicenter experience with the sutureless Perceval valve: clinical and haemodynamic outcomes up to 5 years in over 700 patients. *Eur J Cardiothorac Surg* 2016;49:234-41. <http://doi.org/f8bs52>

13. Bouhout I, Noly PE, Parisi A, Bouchard D. First case of Perceval S prosthesis early structural valve deterioration: Not an easy reoperation. *J Thorac Cardiovasc Surg* 2016; 152:e71-3. <http://doi.org/cq4w>

14. Amr G, Ghoneim A, Giraldeau G, Demers P. First case of a sutureless Perceval valve delayed proximal migration. *J Thorac Cardiovasc Surg* 2017;153:e21-e23. <http://doi.org/cq4x>

15. Meco M, Montisci A, Miceli A, Panisi P, Donatelli F, Cirri S, et al. Sutureless Perceval Aortic Valve Versus Conventional Stented Bioprostheses: Meta-Analysis of Postoperative and Midterm Results in Isolated Aortic Valve Replacement. *J Am Heart Assoc* 2018 Feb 16;7(4). pii: e006091. <http://doi.org/cq4z>