

Coronary-Pulmonary Artery Fistula

Fístula coronaria-pulmonar

RICARDO LEVIN, MARCELA DEGRANGE, RAFAEL PORCILE

We describe the case of a 37-year-old male patient hospitalized due to progressive angina with T-wave inversion in the inferior wall and positive enzyme markers. Coronary angiography showed the presence of a fistula from the proximal right coronary artery to the pulmonary circulation.

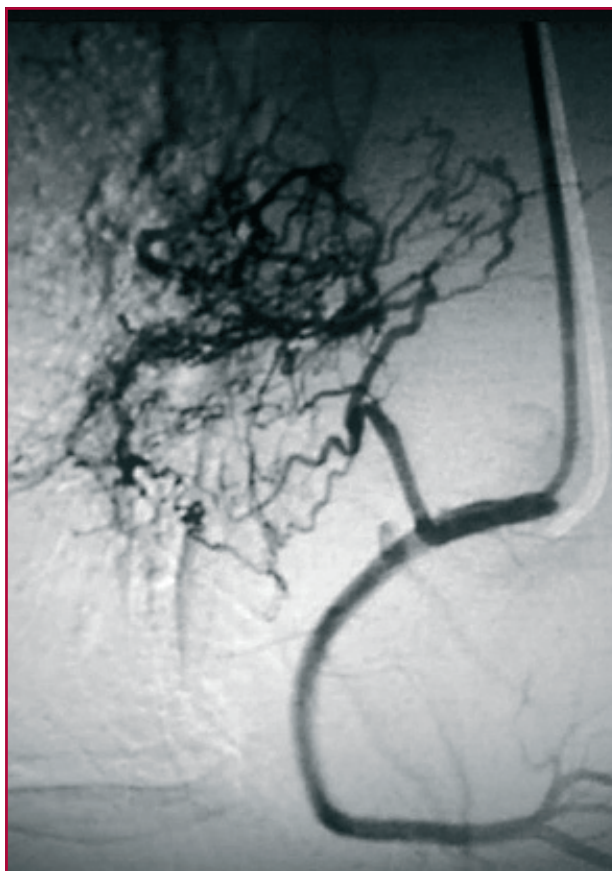
Coronary fistulas are rare anomalies, characterized by abnormal communication between a coronary artery and other vessels or a heart chamber. They are usually congenital, but they can also be secondary to inflammatory processes, traumas, or percutaneous or surgical procedures. (1, 2) Their course may be asymptomatic and sometimes the result of a finding in a coronary angiography or pathological anatomy study; they may also present symptoms consistent with ischemic heart disease, as in our case, whose clinic depends on the caliber and magnitude of the abnormal communication. (3)

The most common origin is from the right coronary artery (50% of cases) and drainage into the right cavities is the observed destination in more than 90% of cases, while 15% communicate with the pulmonary circulation. Depending on the drainage site, they are classified into 5 types: type I, drainage into the right atrium; type II, drainage into the right ventricle; type III, connection with the pulmonary circulation; type IV, communication with the left atrium; and type V, drainage into the left ventricle. (4)

Large fistulas can develop various complications, such as thrombosis, rupture, arrhythmias, pulmonary hypertension, heart failure or myocardial ischemia secondary to coronary steal. There is no definite consensus regarding its treatment, although in symptomatic patients, the fistula can be resolved by either surgical or percutaneous closure with occluding or spiral devices, an option chosen for our patient. The patient remained asymptomatic one year after the procedure. (5)

Conflicts of interest

None declared (See authors' conflicts of interest forms on the website/ Supplementary Material).



REFERENCES

1. Gowda RM, Vasavada BC, Khan IA. Coronary artery fistulas: clinical and therapeutic considerations. *Int J Cardiol* 2006;107:7-10. <http://doi.org/ctk2fr>
2. Loukas M, Germain S, Gabriel A, John A, Tubbs RS, Spicer D. Coronary artery fistula: a review. *Cardiovasc Pathol* 2015;24:141-8. <http://doi.org/cnrx>
3. Cieslinski G, Rapprich B, Kober G. Coronary anomalies: incidence and importance. *Clin Cardiol* 1993;16:711-5. <http://doi.org/ckw4ft>
4. Musante C, Muñoz Giacomelli E, Pérez Baliño P. Fístula coronario-pulmonar. *Rev Argent Cardiol* 2011;79:267-8.
5. Armsby LR, Keane JF, Sherwood MC, Forbess JM, Perry SB, Lock JE. Management of coronary artery fistulae. Patient selection and results of transcatheter closure. *J Am Coll Cardiol* 2002;39:1026-32. <http://doi.org/chgs55>