

Suboptimal Reperfusion

Reperusión subóptima

WHAT IS CORONARY REPERFUSION?

Coronary reperfusion is the restitution of normal coronary blood flow after the obstruction of a coronary artery. This is achieved either by physical methods such as coronary angioplasty or through pharmacological agents such as fibrinolytic drugs, which dissolve the blood clot in the coronary artery.

HOW IS CORONARY REPERFUSION EVALUATED?

Visually, coronary reperfusion is evaluated assessing the speed with which the coronary artery fills with blood once the angioplasty is performed and this is determined through a flow scale called TIMI.

TIMI goes from 0 (artery without blood flow) to 3 (artery with normal blood flow that fills in less than 3 beats) (Figure 1).

Also, reperfusion is evaluated with the simple and modest electrocardiogram, which defines whether the abnormalities that appear due to the coronary obstruction leading to infarction have disappeared and the myocardium is adequately perfused (Figure 2).

In some patients who achieve optimal coronary flow after angioplasty, there may be persistence of the electrocardiographic abnormalities, indicating that the cardiac muscle does not yet receive normal blood perfusion.

This phenomenon is called “suboptimal reperfusion”.

WHY IS OPTIMAL REPERFUSION IMPORTANT?

Several studies have shown that the normalization of the electrocardiogram is important, since in patients where this does not happen, the prognosis is not as good as in those in which it is normalized, and a larger scar (infarction) is formed than was initially assumed.

WHAT FACTORS ARE ASSOCIATED WITH SUBOPTIMAL REPERFUSION?

The following factors are associated with suboptimal reperfusion:

- Anterior wall myocardial infarction
- History of previous revascularization procedures (prior angioplasty or coronary bypass graft surgery)
- Marked delay in performing the angioplasty -the longer, the worse.
- Age >70 years, diabetes and prior ventricular function impairment.

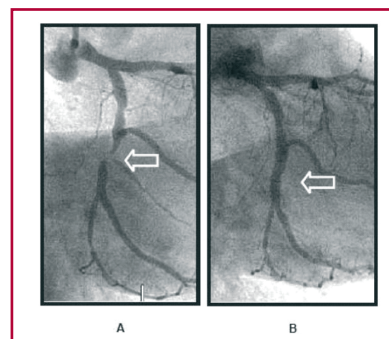


Fig. 1. Right coronary artery: obstructed (A) and without obstruction (B) after the angioplasty (arrow).

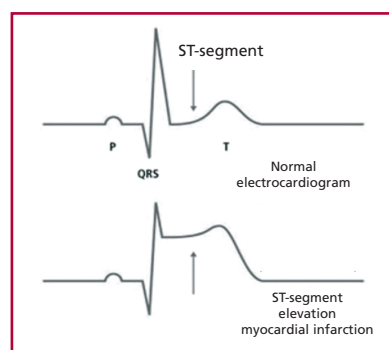
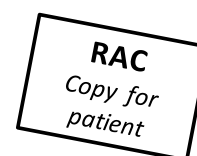

Fig. 2. Normal (upper panel) and pathological (lower panel) electrocardiogram, as observed in myocardial infarction.



Author: Dr. Pablo Merlo
Hospital Bernardino Rivadavia

Editor: Julio Manuel Lewkowicz, MD
Sanatorio Güemes, Buenos Aires

RECOMMENDED BIBLIOGRAPHY

- De Luca G, van 't Hof AW, de Boer MJ, Hoorntje JC, Gosselink AT, Dambrink JH, et al. Impaired myocardial perfusion is a major explanation of the poor outcome observed in patients undergoing primary angioplasty for ST-segment-elevation myocardial infarction and signs of heart failure. *Circulation* 2004;109:958-1.