

Femoral Pseudoaneurysm Treatment by Local Thrombin Injection

Tratamiento del pseudoaneurisma femoral mediante la inyección local de trombina

TOMÁS CÚNEO¹, GUSTAVO PEDERNERA¹, PABLO SPALETRA¹, GUSTAVO AVEGLIANO², GABRIEL PEREA², ALFONSINA CANDIELLO¹, GERARDO NAU¹, LUCIO PADILLA¹, JORGE BELARDI¹, FERNANDO CURA¹

ABSTRACT

Background: Pseudoaneurysm is a rare complication (0.05-0.5%) after interventional procedures using femoral access. There are few registries of local thrombin injection for pseudoaneurysm closure as an alternative treatment to surgery after failed manual compression.

Objective: The aim of this study was to evaluate the safety and efficacy of iatrogenic femoral pseudoaneurysm closure with Doppler ultrasound-guided local thrombin injection.

Methods: Thirty-two patients were included for thrombin injection treatment between March 2007 and June 2016.

Results: Mean age was 64.3 ± 10.2 years. Most pseudoaneurysms were associated with diagnostic or therapeutic cardiac catheterizations (59.3%). Seven patients had received anticoagulant treatment and 21, double antiplatelet therapy. In all cases, prior closure was attempted by manual compression. Mean pseudoaneurysm major diameter was 38 mm. Following treatment, immediate pseudoaneurysm sac thrombosis occurred in 28 patients (87.5%), while 4 patients required a second injection, resulting in 96.8% success rate. Treatment was not effective in only one patient, with subsequent conversion to programmed surgical repair. Mean thrombin dose was 450 units. Only one patient presented with venous thrombosis complication requiring anticoagulant therapy, with good clinical outcome.

Conclusion: Doppler ultrasound-guided local thrombin injection was a safe and effective therapeutic alternative for pseudoaneurysm treatment in patients with femoral pseudoaneurysm refractory to manual compression.

Key words: Aneurysm, False - Thrombin - Thrombosis

RESUMEN

Introducción: El pseudoaneurisma es una complicación ocasional (0,05-0,5%) de los procedimientos intervencionistas cuando se utiliza el acceso femoral. El cierre con inyección local de trombina como alternativa al tratamiento quirúrgico luego de compresión manual fallida cuenta con escasos registros.

Objetivo: Evaluar la seguridad y eficacia del cierre del pseudoaneurisma femoral iatrogénico mediante la inyección local de trombina guiada por ecografía Doppler.

Material y métodos: Entre marzo de 2007 y junio de 2016 se incluyeron 32 pacientes para tratamiento con inyección de trombina.

Resultados: La edad media fue de $64,3 \pm 10,2$ años. La mayoría de los pseudoaneurismas estuvieron asociados con la realización de cateterismos coronarios diagnósticos o terapéuticos (59,3%). Siete pacientes habían recibido tratamiento anticoagulante y 21 doble antiagregación plaquetaria. En todos los casos se intentó previamente el cierre por compresión manual. La media del diámetro mayor de los pseudoaneurismas fue de 38 mm. Luego del tratamiento, la trombosis inmediata del saco ocurrió en 28 pacientes (87,5%), mientras que 4 pacientes requirieron una segunda inyección, lo que determinó un éxito del 96,8%. En un solo paciente este tratamiento no fue efectivo, con posterior conversión a reparación quirúrgica programada. La dosis media de trombina fue de 450 unidades. Un único paciente presentó complicación trombotica venosa que requirió terapia anticoagulante, con buena evolución clínica.

Conclusión: El tratamiento del pseudoaneurisma con inyección local de trombina guiada por eco-Doppler fue una alternativa terapéutica segura y eficaz para pacientes con pseudoaneurisma femoral refractarios a la compresión manual.

Palabras clave: Aneurisma falso - Trombina - Trombosis

Abbreviations

IQR	Interquartile range
-----	---------------------

REV ARGENT CARDIOL 2017;85:227-231. <http://dx.doi.org/10.7775/RAC.v85.i3.9494>

Received: 10/26/2016 - Accepted: 02/08/2017

Address for reprints: Dr. Tomás Cúneo - Blanco Encalada 1543 - (1428) Ciudad Autónoma de Buenos Aires, Argentina - e-mail: tomascuneo83@gmail.com

Department of Interventional Cardiology and Endovascular Therapy. Instituto Cardiovascular de Buenos Aires. Sanatorio Anchorena. Buenos Aires, Argentina

¹ Department of Interventional Cardiology and Endovascular Therapy - ICBA

² Ultrasound Unit- ICBA

INTRODUCTION

Pseudoaneurysm is an occasional complication (0.05-0.5%) after interventional procedures with femoral access, with a clear association with patient morbidity and mortality. (1-4) This false aneurysm consists of a pulsating bubble hematoma (false aneurysm) receiving blood that enters and unloads through a canal (neck) communicating with the punctured vessel. It usually appears within the first 3 days after withdrawal of the introducer and the risk of rupture increases at higher diameters, turning its treatment mandatory for diameters above 25 mm. (5) For many years, surgical repair was considered the method of choice in most worldwide centers. However, it presents several disadvantages: need for anesthesia, long hospitalizations and procedure-related complications as suture dehiscence, local infection, hemorrhage and need to interrupt antiplatelet/anticoagulant treatment in patients requiring it. (6, 7) Ultrasound-guided manual compression is an economic and non-invasive procedure, with high success rate and low complication rate. Despite these advantages and wide utilization, there are limitations to its implementation depending on anatomical characteristics, pseudoaneurysm location and patient degree of obesity. In addition, this technique generates an important discomfort in the patient and has a considerable rate of recurrence. (8-10)

Although the thrombin closure technique has been used for some years, there are few registries on this treatment and its mid-term results. The aim of the present study was thus to assess the safety and efficacy of iatrogenic femoral pseudoaneurysm percutaneous treatment with Doppler ultrasound-guided local thrombin administration.

METHODS

All patients presenting with pseudoaneurysm of the femoral artery as a percutaneous cardiovascular or electrophysiological procedure complication between March 2007 and June 2016 were included in the study. Diagnosis was based on clinical and echocardiographic criteria. Clinical criteria included presence of a pulsatile, generally painful hematoma with bruit on auscultation, which was confirmed by Doppler ultrasound, using a Philips Medical Systems ultrasound machine equipped with 3-4-MHz transducer. Figure 1 shows a color Doppler ultrasound image evidencing a cross-sectional view of the pseudoaneurysm communicating below with the femoral artery. Doppler ultrasound also allows a differential diagnosis mainly of arteriovenous fistulas, abscesses, deep vein thrombosis and hematomas. It was also used to confirm color flow in the femoral artery and vein.

Human thrombin (Tissucol™ and/or Beriplast™, containing a vial of 1000 U thrombin) was used in all cases. Thrombin activates fibrinogen breakdown to fibrin monomers, which bind to factor XIIIa in the presence of calcium (Ca²⁺), producing the immediate formation of a fibrin clot (thrombus). Thrombin preparation followed standard product procedure. The only limitations for thrombin treatment were patients with history of thrombin hypersensitivity, local infection at the puncture site, skin necrosis secondary to compression of neighboring structures and pseudoaneurysm rupture (requiring surgical treatment).

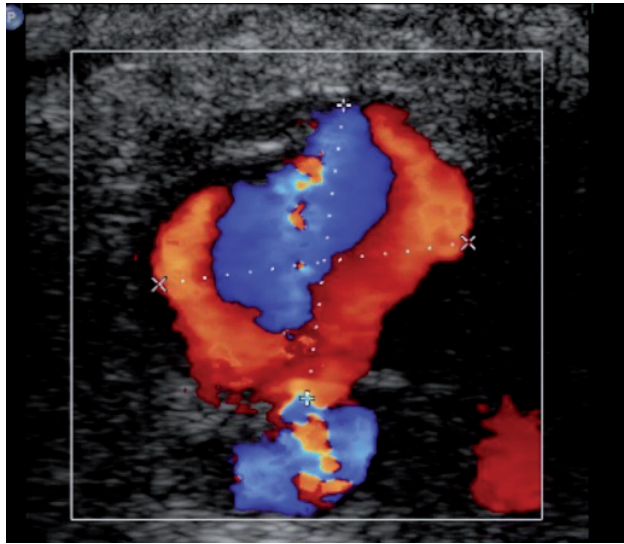


Fig. 1. Color Doppler ultrasound image showing a transverse section of the pseudoaneurysm communicating below with the femoral artery.

The efficacy or effectiveness of the method resulted from adequate, satisfactory procedures, i.e. absence of flow inside the pseudoaneurysm after thrombin injection. The safety of the method depended on the presence of complications after thrombin closure: venous thrombosis, requirement of blood product transfusion, distal embolization of the affected limb, need for emergency repair surgery, acute myocardial infarction, stroke or death.

Technique description

Adequate inguinal asepsis is performed. Correct ultrasound visualization of the pseudoaneurysm is required from an angle that simultaneously allows the intervention (mass puncture). In addition, it is convenient to confirm distal vessel permeability prior to the procedure both with Doppler ultrasound as pulse palpation. The puncture is performed with 21G needle and 10 ml syringe loaded with saline (without Luer lock) under ultrasound guidance in the central position of the pseudoaneurysmal sac. Puncture site is confirmed by saline injection with color Doppler ultrasound visualization. Without withdrawing the needle the 10 ml syringe is exchanged by a 1ml (tuberculin) syringe with thrombin solution. Human thrombin (500 IU/ml solution) is slowly injected during 10 to 30 seconds until interruption of blood flow within the aneurysmal sac is evidenced by color Doppler ultrasound (Figure 2). This maneuver may be performed with or without femoral artery compression to decrease flow within the cavity. In most cases, immediate sac thrombosis is achieved. In cases of incomplete thrombosis or multilocular pseudoaneurysms, other lobules closer to the fistula trajectory must be repunctured. There are no established doses, as they will depend on cavity size, flow inside it and injection site. After the injection, a soft inguinal compression is performed for 15 minutes. Presence of distal pulses should be controlled again and triphasic flow is verified by Doppler ultrasound. A local bandage is placed and complete limb rest is indicated for 8 hours (Figure 3).

Statistical analysis

Quantitative variables are expressed as frequencies or per-

centages and qualitative variables as mean \pm standard deviation or median \pm interquartile range (IQR). SPSS version 22.0 was used to order and organize the data.

Ethical considerations

The protocol was performed according to the Declaration of Helsinki principles, respecting patient's data protection rights. The protocol was approved by our institutional Ethics Committee.

RESULTS

A total of 156 patients presenting femoral pseudoaneurysm as percutaneous procedure complication were assessed during the study interval. In all cases pseudoaneurysm closure was attempted by manual compression with or without ultrasound guidance. This procedure failed in 73 patients (46.7%) making necessary another closure method, which was decided by the treating medical team. In 41 patients, surgical repair was the treatment of choice. In the remaining 32 patients, Doppler ultrasound-guided local thrombin injection was decided. None of these latter patients was excluded, either for pseudoaneurysm dimensions, closeness to the femoral artery, or fistula

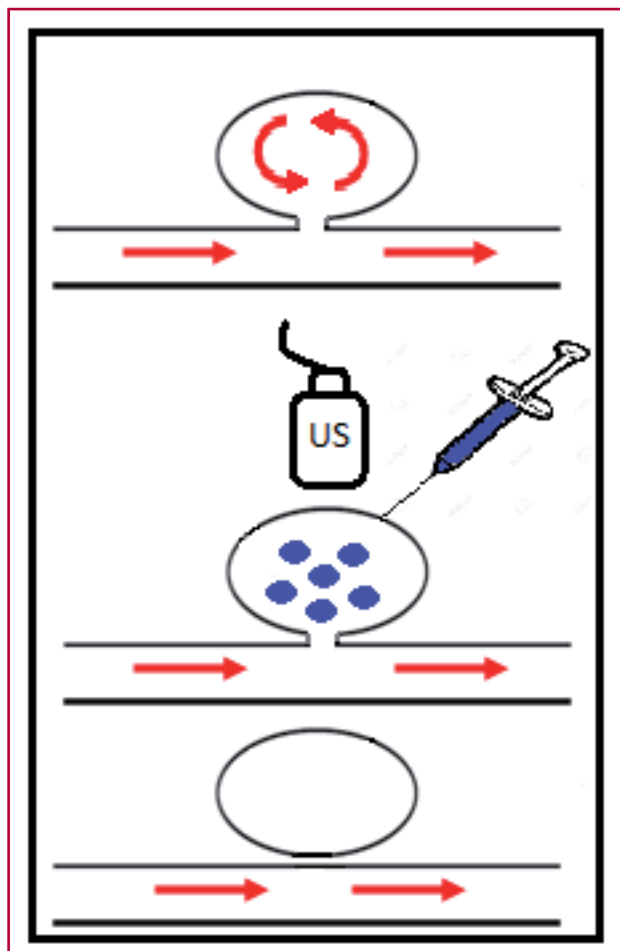


Fig. 2. Thrombin injection technique (see text for description). US: ultrasound

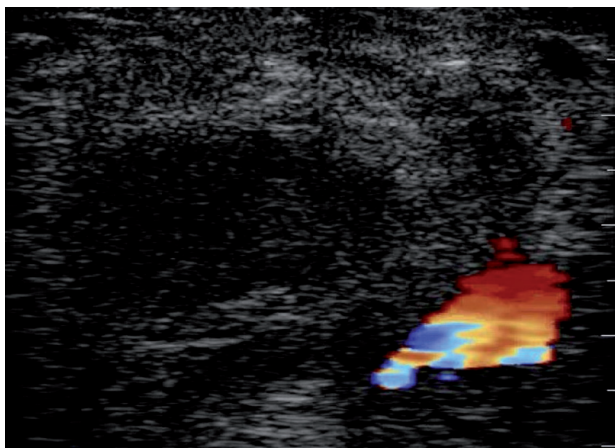


Fig. 3. Image after thrombin injection and compression. Notice absence of flow within the cavity corresponding to the thrombosed pseudoaneurysm, and below to the right is the slightly compressed artery.

size and trajectory.

Mean age was 64.3 ± 10.2 years (IQR 32-86 years), 59.3 % of patients were men, and mean body mass index was 27 ± 6 . In 87.5% of cases patients were hypertensive, 62.5% had dyslipidemia, 21.8% diabetes and 50% were smokers. Among patients, 37.5% had history of cardiac arrhythmia, 28.1% of acute myocardial infarction and 15.6% of heart valve disease. Laboratory tests revealed that patients had $38.4 \pm 7.2\%$ hematocrit, 12.5 ± 2.7 mg/dl hemoglobin, mean platelet count of 215,739 (IQR 131,000-334,000), and creatinine clearance of 62.3 ± 30.5 ml/min. Seven patients (21.8%) were receiving anticoagulant treatment with warfarin or acenocoumarol and 21 patients (65.6%) double antiplatelet therapy at the time of the procedure (Table 1). None of these medications was discontinued. Most pseudoaneurysms (59.3%) were associated with diagnostic or therapeutic coronary artery procedures. The rest were secondary to other percutaneous procedures: peripheral or renal angioplasties, radiofrequency ablation, myocardial biopsy and transcatheter aortic valve implantation. A 7 Fr sheath was used in 21.8% of patients and a 6 Fr sheath in the remaining cases. Average major pseudoaneurysm diameter was 38 mm (IQR 13-58) and average neck length was 18 mm (IQR 7-26). In most patients (84.3%) the common femoral artery was the affected vessel (Table 2). Twenty four percent of pseudoaneurysms were multilocular. Red blood cell transfusion was required in 4 cases due to hematocrit drop greater than 10 points prior to pseudoaneurysm closure.

Diagnosis was immediate (0-2 days) in 25% of patients and late (> 2 days) in the remaining 75% of cases. Median time for percutaneous closure was 6.1 days (IQR 1-120), because one patient attended the follow-up visit 4 months after the intervention. In all cases, thrombin closure was performed within 24 hours of pseudoaneurysm diagnosis. Immediate complete pseudoaneurysm thrombosis occurred in 28 of

the 32 patients (87.5%), while 4 patients required a second injection on the following day, achieving an overall success rate of 96.8%. Thrombin treatment was not effective in only one patient, requiring conversion to programmed surgical repair, without complications. Mean thrombin dose was 450 IU (IQR 200-1000). There was no direct correlation between pseudoaneurysm size and required thrombin dose. No arterial embolic events were encountered. Only one patient presented a venous thrombotic complication with development of deep vein thrombosis and pulmonary thromboembolism, needing anticoagulant therapy with good clinical outcome. A second patient developed local infection at the puncture site which reversed with oral antibiotic treatment.

Median follow-up was 4.3 years (IQR 1-8 years), with ambulatory clinic appointments and telephone calls in all cases, including a control Doppler ultrasound at one week and 30 days after the procedure. There were no late recurrences. During long-term follow-up, 4 patients died for causes unrelated with the procedure (three from cancer and one for progression of an underlying coronary artery disease). The remaining 28 patients could resume their usual activities without problems.

DISCUSSION

The exponential increase of endovascular treatment for a wide range of cardiovascular, coronary, peripheral and structural diseases has drawn special attention

Age, years (range)	64.3 (32-86)
Gender, n (%)	
- Female	13 (40.6)
- Male	19 (59.3)
BMI	
- Normal <25	7 (21.8)
- Overweight 25–29.9	17 (53.1)
- Obesity >30	8 (25)
Hypertension	28 (87.5)
Dyslipidemia	20 (62.5)
Diabetes	7 (21.8)
Smoking	16 (50)
Medication, n (%)	
- Anticoagulant (warfarin or acenocoumarol)	7 (21.8)
- Antiplatelet therapy (ASA + Clopidogrel)	21 (65.6)
Laboratory tests	
- Hematocrit	38.4±7.2%
- Hemoglobin	12.5±2.7 mg/dl
- Platelets	215,739 (IQR 131,000–334,000)
- Creatinine clearance	62.3±30.5 ml/min

BMI: Body mass index. ASA: acetylsalicylic acid. IQR: Interquartile range.

Table 1. Baseline population characteristics

Procedure, n (%)	
- Coronary angiography and coronary angioplasty	19 (59.3)
- Peripheral angioplasty	3 (9.3)
- Renal angioplasty	2 (6.2)
- Electrophysiological procedures	6 (18.7)
- Myocardial biopsy	1 (3.1)
- TAVI	1 (3.1)
Pseudoaneurysm origin, n (%)	
- Common femoral artery	27 (84.3)
- Superficial femoral artery	3 (9.3)
- External iliac artery	2 (6.2)
Sheath size, n (%)	
- 7 Fr	7 (21.8)
- 6 Fr	25 (78.1)
Major pseudoaneurysm diameter, mm (range)	38 (13-58)
Average neck length, mm (range)	18 (7-26)
Closure time, days, median (range)	6.1 (1-120)

TAVI: Transcatheter aortic valve implantation.

Table 2. Technical characteristics of the procedure

to the possible complications of the vascular access. Although its incidence is low, femoral pseudoaneurysm is one of the local vascular complications most frequently associated with percutaneous procedures. Its emergence may produce local pain, rupture, distal embolism, neurologic symptoms due to local compression, underlying cutaneous necrosis and anemia. It also demands prolonged hospital stay. (11)

Conservative management of small size pseudoaneurysms was evaluated in non-coagulated asymptomatic patients. However, the difficulty to predict the time of spontaneous closure and the costs of serial echocardiographic control studies discouraged this practice. (12, 13) The first therapeutic option is ultrasound-guided or not guided manual compression. This method is nevertheless associated to unpredictable success rates and the procedure is very painful for the patient. The compression is relatively inefficient as the tumor does not allow applying pressure on a precise point of the artery and there is frequent laceration and inflammation of the subcutaneous cellular tissue and skin due to energetic compressions. (9, 10) Doppler ultrasound-guided local thrombin injection has the advantage of being a low cost, technically simple procedure in experienced hands, not needing sedation, less traumatic and feasible to perform at the patient's bedside, as shown in this study.

Our study obtained a success rate similar to that of centers with a large number of cases, (11, 14, 16) achieving total absence of flow in the virtual cavity in most patients. Only one patient presented with deep vein thrombosis/pulmonary thromboembolism without hemodynamic decompensation. He required anticoagulant therapy and was discharged without complications and with posterior good outcome. This complication could probably be ascribed to injection in the femoral vein instead of inside the aneurysmal cavity.

In the last years there has been a migration from femoral to radial access for coronary artery interventions, which is producing a clear reduction of these complications while increasing patient comfort and hospital operative efficiency. However, many peripheral or structural procedures still require femoral access. Careful management of femoral artery puncture to insert the introducer and the time of hemostasis is mandatory to avoid vascular complications.

Limitations

The results of this registry correspond to a small cohort of highly selected patients treated with thrombin injection, in whom manual compression failed, and with mid-term follow-up.

CONCLUSIONS

Pseudoaneurysm treatment by Doppler ultrasound-guided local thrombin injection is associated with a high rate of effectiveness and safety, becoming a therapeutic alternative for patients with femoral pseudoaneurysm refractory to manual compression, thus

avoiding surgical treatment. Anticoagulant and/or antiplatelet therapy did not interfere in the success of pseudoaneurysm closure with thrombin. Therefore, we consider that local thrombin closure should be the treatment of choice after failure of pseudoaneurysm compression.

Conflicts of interest

None declared. (See authors' conflicts of interest forms on the website/Supplementary material).

REFERENCES

- Hessel SI, Adams DF, Abrams HL. Complications of angiography. *Radiology* 1981;138:273-81. <http://doi.org/b6sg>
- Katzenschlager R, Ugurloughlu A, Ahmadi A, Hülsmann M, Koppensteiner R, Larch E, et al. Incidence of pseudoaneurysm after diagnostic and therapeutic angiography. *Radiology* 1995;195:463-6. <http://doi.org/b6sh>
- Righini MQI, Quéré I, Laroche IP. Treatment of postcatheterization femoral false aneurysms. *I Mal Vasc* 2004;29:63-72. <http://doi.org/dpz827>
- Hughes MI, McCall IM, Nott DM, Padley SPI. Treatment of iatrogenic femoral artery pseudoaneurysms using ultrasound-guided injection of thrombin. *Clin Radiol* 2000;55:749-51. <http://doi.org/b8vtf3>
- Moreiras JM, González IC. Manual de Hemodinamia e intervencionismo coronario. 2a ed. España : Edit. Marban, 2013
- Lumsden AB, Miller IM, Kosinski AS, Allen RC, Dodson TF, Salam AA, et al. A prospective evaluation of surgically treated groin complications following percutaneous cardiac procedures. *Am Surg* 1994;60:132-7. <http://doi.org/bs4cjm>
- Piffaretti G, Mariscalco G, Tozzi M, Rivolta N, Castelli P, Sala A. Predictive factors of complications after surgical repair of iatrogenic femoral pseudoaneurysms. *World J Surg* 2011;35:911-6. <http://doi.org/bs4cjm>
- Fellmeth B, Roberts A, Bookstein J, Freischlag J, Forsythe J, Buckner N, et al. Postangiographic femoral artery injuries: nonsurgical repair with US guided compression. *Radiology* 1991;178:671-5. <http://doi.org/b6sj>
- Paschalidis M, Theiss W, Kölling K, Busch R, Schömig A. Randomised comparison of manual compression repair versus ultrasound guided compression repair of postcatheterisation femoral pseudoaneurysms. *Heart* 2006;92:251-2. <http://doi.org/dv9bk7>
- Cox GS, Young JR, Gray BH, Grubb MW, Hertzner NR. Ultrasound-guided compression repair of postcatheterization pseudoaneurysms: results of treatment in one hundred cases. *J VascSurg* 1994;19:683-6. <http://doi.org/fxh8v4>
- La Perna L, Olin JW, Goines D, Childs MB, Ouriel K. Ultrasound-Guided Thrombin Injection for the Treatment of Postcatheterization Pseudoaneurysms. *Circulation* 2000;102:2391-5. <http://doi.org/b6sk>
- Kresowik TF, Khoury MD, Miller BV, Winniford MD, Shamma AR, Sharp WJ, et al. A prospective study of the incidence and natural history of femoral vascular complications after percutaneous transluminal coronary angioplasty. *J Vasc Surg* 1991;13:328-36. <http://doi.org/bscmtw>
- Toursarkissian B, Allen BT, Petrincec D, Petrincec D, Thompson RW, Rubin BG, Reilly JM et al. Spontaneous closure of selected iatrogenic pseudoaneurysms and arteriovenous fistulae. *J Vasc Surg* 1997;25:803-8. <http://doi.org/d6vg3d>
- Sultan S, Nicholls S, Madhavan P, Colgan MP, Moore D, Shanik G. Ultrasound Guided Human Thrombin Injection. A New Modality in the Management of Femoral Artery Pseudo-aneurysms. *Eur J Vasc Endovasc Surg* 2001;22:542-5. <http://doi.org/bfkxv6>
- Weinmann EE, Chayen D, Kobzantzev ZV, Zaretsky M, Bass A. Treatment of postcatheterisation false aneurysms: ultrasound-guided compression vs ultrasound-guided thrombin injection. *Eur Vasc Endovasc Surg* 2002;23:68-72. <http://doi.org/bj7xs4>
- Coley BD, Roberts AC, Fellmeth BD, Valji K, Bookstein II, Hye RI. Postangiographic femoral artery pseudoaneurysms: further experience with US-guided compression repair. *Radiology* 1995;194:307-11. <http://doi.org/b6sp>