

Calcified Necrosis of the Mitral Annulus

Necrosis cálcica del anillo mitral

MARCELO RODRIGO EGUINO¹, NATALIO GASTALDELLO²

Calcified necrosis of the mitral annulus is also known as “liquefactive necrosis”, mitral annular calcification, or caseous abscess. (1, 2) Its prevalence is low, <0.1% (1), preferentially occurring in elderly subjects, female patients, and patients with diabetes or calcium metabolism disorders. (2) In general, it is an echocardiographic finding with asymptomatic course. (2, 3) The following images correspond to a 68-year old diabetic, hypertensive female patient with a dual-chamber permanent pacemaker, who had recently been diagnosed with a tumor in the left atrium in the context of dyspnea on exertion and was referred for outpatient transesophageal echocardiography. Figure

1 shows a hyperechogenic cystic lesion at the level of the posterior mitral annulus, with anechoic content and no passage of contrast agent. Figure 2 shows calcified necrosis and its cross sectional image.

It is important to be aware of this condition when making the differential diagnosis of mitral abscess (which was ruled out due to different location and absence of clinical features) and of aneurysmal dilatation of the circumflex artery (presence of flow).

Conflicts of interest

None declared (See authors' conflicts of interest forms on the website/ Supplementary Material).

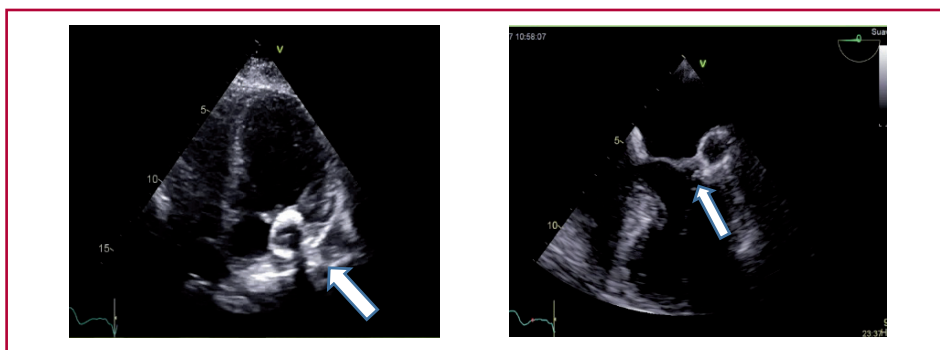


Fig. 1. Transthoracic and transesophageal echocardiography. Four-chamber view at 0°.

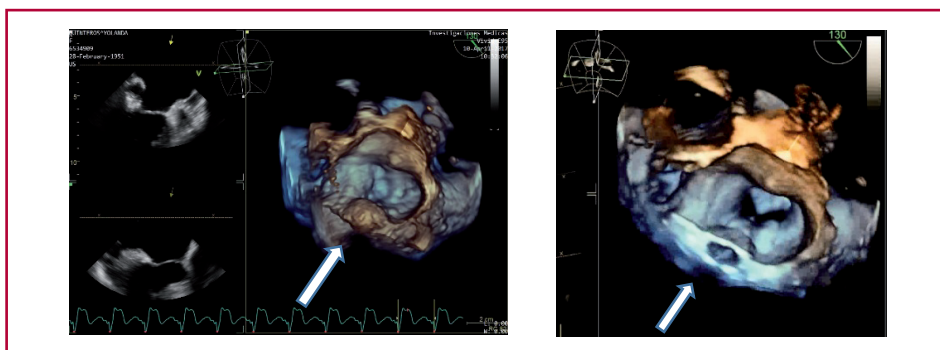


Fig. 2. 3D Transesophageal echocardiography zoom image, surgeon's view.

REFERENCES

1. Kuwauchi S, Watanabe S, Abe K, Yamasaki M, Ito J, Mizuno A, et al. Caseous calcification of mitral annulus. *Cardiovasc Diagn Ther* 2013;3:108-10.

2. Garcia-Ibarrondo N, Lang R. Caseous Calcification of the Mitral Annulus, a Rare Echocardiographic Finding. *Rev Esp Cardiol* 2011;64:828-31. <http://doi.org/cv8wrt>

3. Martínez de Alegría Alonso A, Delgado Sánchez-Gracián C, Fernández Pérez G, Peña Gil C. Liquefactive necrosis of the mitral ring. *Radiología* 2010;52:157-61. <http://doi.org/cfrnz4>

Rev Argent Cardiol 2017;85:525. <http://dx.doi.org/10.7775.rac.v85.i6.12131>

Address for reprints: Marcelo R. Eguino. e-mail: marceloeguino2004@hotmail.com

¹ Investigaciones Médicas

² Medical Research