

Clinical and Echocardiographic Impact in Patients Undergoing Percutaneous Closure of Paravalvular Leaks

Impacto clínico y ecocardiográfico en pacientes sometidos a cierre percutáneo de fugas paravalvulares

GUSTAVO PEDERNERA^{MTSAC, 1}, GERARDO NAU^{MTSAC, 1}, GUSTAVO AVEGLIANO^{MTSAC, 2}, RICARDO RONDEROS^{MTSAC, 2}, GERMÁN HENESTROSA¹, JUAN M. VRANCIC^{MTSAC, 3}, FERNANDO PICCININI^{MTSAC, 3}, MARCELO TRIVI^{MTSAC, 4}, FERNANDO CURA^{MTSAC, 1}

ABSTRACT

Background: The development of paravalvular leaks after surgical valve replacement is a rare complication but with high morbidity and mortality. Percutaneous closure is an alternative to surgery in high-risk surgical patients. However, as it is sporadically performed due to its complexity, there is limited information on its effectiveness and safety.

Objectives: The aim of this study was to assess the mid-term effectiveness and safety of the procedure and to report the techniques employed.

Methods: Both in-hospital and mid-term clinical and echocardiographic evolution and procedural complications of all patients undergoing percutaneous leak closure were analyzed.

Results: Percutaneous closure of 13 leaks (6 aortic and 7 mitral) was performed in 9 patients. Technical success was achieved in 100% of cases, with a marked improvement in functional class and laboratory parameters. Paravalvular regurgitation assessed by Doppler echocardiography was minimal or mild after the procedure as well as during mid-term follow-up. In the long-term follow-up (22 months, interquartile range: 3-44), all patients survived with no major events and good functional class. Two patients operated on via transapical access, required red blood cell transfusion after the procedure, with favorable outcome.

Conclusions: Percutaneous closure of paravalvular leaks is a safe and efficient procedure, enabling a substantial improvement of functional class. This treatment should be considered an option for high-risk surgical patients.

Key words: Prosthetic Leak - Prosthetic Dysfunction - Transesophageal Echocardiography

RESUMEN

Introducción: El desarrollo de fugas paravalvulares luego del reemplazo valvular es un fenómeno poco frecuente, pero de gran repercusión clínica y morbimortalidad. El cierre percutáneo es una alternativa a la cirugía en pacientes con riesgo quirúrgico alto; sin embargo, estas intervenciones se realizan esporádicamente debido a su complejidad, por lo que contamos con escasa información sobre su eficacia y seguridad.

Objetivos: Evaluar la efectividad y seguridad del procedimiento, la evolución a mediano plazo y comunicar las técnicas utilizadas.

Material y métodos: Se analizaron la evolución clínica y ecocardiográfica tanto hospitalaria como a mediano plazo y las complicaciones del procedimiento de todos los pacientes sometidos a cierre de fugas paravalvulares.

Resultados: Se trataron 13 fugas paravalvulares en 9 pacientes (6 en posición aórtica y 7 mitrales). El éxito técnico se logró en el 100% de los casos, evidenciando una marcada mejoría de la clase funcional y de parámetros de laboratorio. Esto permitió que la regurgitación perivalvular, evaluada por ecocardiograma Doppler, fuera mínima o leve luego del procedimiento y a mediano plazo. En el seguimiento alejado (22 meses, rango intercuartil: 3-44), todos los pacientes sobrevivieron sin eventos mayores y mantuvieron una buena clase funcional. Dos pacientes en los que se practicó el acceso transapical requirieron transfusión de glóbulos rojos luego del procedimiento, con buena evolución.

Conclusiones: El cierre percutáneo de fugas paravalvulares es un procedimiento seguro y eficaz, que permite una mejoría sustancial de la clase funcional. Este tratamiento debería considerarse una opción para pacientes que poseen un riesgo quirúrgico elevado.

Palabras clave: Dehiscencia paravalvular - Disfunción protésica - Ecocardiograma transesofágico

REV ARGENT CARDIOL 2016;84:446-452. <http://dx.doi.org/10.7775/rac.v84.i5.8545>

Received: 04/29/2016 – Accepted: 08/17/2016

Address for reprints: Dr. Gustavo Pedernera - Blanco Encalada 1543 - (1428) Ciudad Autónoma de Buenos Aires, Argentina - e-mail: gpedernera@icba.com.ar

^{MTSAC} Instituto Cardiovascular de Buenos Aires (ICBA)

^{MTSAC} Full Member of the Argentine Society of Cardiology

¹ Interventional Cardiology and Endovascular Therapy Unit

² Diagnostic Imaging Unit

³ Cardiac Surgery Unit

⁴ Department of Cardiology

Abbreviations

2D	Two-dimensional	PVL	Paravalvular leaks
3D	Three-dimensional	TEE	Transesophageal echocardiography
FC	Functional class		

INTRODUCTION

Paravalvular leaks (PVL) are an uncommon complication after heart valve surgery. However, echocardiographic studies reveal their presence in 2-17% of valve replacements, with an incidence of 2 to 10% in aortic position and 7-17% in mitral position. (1-4) Only 5-10% PVL will require treatment, evidenced by signs and symptoms of heart failure, hemolytic anemia, arrhythmias, and infectious endocarditis. (1)

Surgery with a new re-operation has been the treatment of choice. However, this option entails high morbidity and mortality and very disparate clinical outcomes, leading to mortality ranging between 15% and 37%. (4-6) Although PVL percutaneous repair was first performed in 1992; there has been a growing interest in the last decade with the development and innovation of devices and catheter and imaging techniques. Currently, the literature reports few cases, with clinical and technical success that ranges between 63% and 100%, mortality of 9% to 20% and varied percentage of conversion to surgery. (2, 7-12) Likewise, mid-and long-term follow-up is uncertain, limiting existing data to the acute or subacute stage. (10, 13-16)

The present analysis was conducted to determine the clinical efficacy and safety of PVL closure beyond the acute closure period, the durability of the clinical benefit and the functional evolution of residual valve regurgitation. In addition, evaluation techniques, therapeutic approaches and closure techniques for each type of PVL are described with the aim of potentially helping to establish standards of care for the treatment of this entity.

METHODS

From August 2010 to October 2015, 13 percutaneous closures of PVL were performed in 9 consecutive patients selected for the procedure. Mean population age was 64 ± 13.8 years and surgical risk, assessed through the logistic EuroSCORE, presented an average score of 29% (17) (Table 1).

The procedure was indicated for heart failure in most patients (89%), who were in functional class (FC) III-IV, and for hemolytic anemia (11%), in the absence of infectious endocarditis. In all cases, treatment decision was assessed by the intervening physicians, until the creation of the Heart Team in 2011, in which treatment strategy was decided by a group of professionals specialized in clinical cardiology, interventionists, electrophysiologists, surgeons, and heart failure and imaging experts, who concluded that reoperation poses an unreasonable risk.

No patient in whom percutaneous treatment had been decided was excluded, nor was the access or closure strategy changed. To carry out the procedure, patients had to meet certain clinical echocardiographic and angiographic charac-

Table 1. Baseline population characteristics (n=9)

Age, years	64 ± 13.8
Male gender, %	55
Comorbidities	
HTN, %	55
DM, %	22
Atrial Fibrillation, %	22
CRF (GFR < 60 ml/min), %	55
Logistic EuroSCORE, %	29
Time since last surgery to closure procedure, months (median)	165 (IQR 51-280)
PM carriers, %	33
Prosthetic valves	
Mechanical, %	67
Biological, %	33
Mechanical aortic, %	22.2
Biological aortic, %	22.2
Mechanical mitral, %	44.4
Biological mitral, %	11.2
PVL location (hour)*	
11-3	12
11-3	1
3-7	6
12	12-3
	6
Symptomatology	
CHF, %	88.8
Hemolytic anemia, %	11.2
History of previous endocarditis, %	33
Ventricular function (TDE), %	52±6
Pulmonary systolic pressure (TDE), (mmHg)	54.2 ± 11

HTN: Hypertension. DM: Diabetes mellitus. CRF: Chronic renal failure, GFR: Glomerular filtration rate. IQR: Interquartile range. PM: Pacemaker. PVL: Paravalvular leaks. CHF: Congestive heart failure, TDE: Transthoracic Doppler echocardiography

* Location of periprosthetic leaks according to the classification previously used by Ruiz et al. (12)

teristics, described below. The FC was defined according to the New York Heart Association (NYHA) classification scale, while symptomatic hemolytic anemia was defined with plasma hemoglobin ≤ 10 g/dl, associated with hemolytic profile data (lactate dehydrogenase ≥ 600 U/l and haptoglobin ≤ 10 mg/dl) without any other source of blood loss. (12-18)

A previous transthoracic echocardiographic evaluation

and a posterior three-dimensional (3D) TEE was performed in all patients. These studies were carried out by a specialized cardiologist with Philips IE33 ultrasound system with S5-1 and X3-1 transthoracic and 7-2 MHz X7-1 transesophageal transducers. Two-dimensional (2D) transthoracic echocardiographic images were obtained at different projection planes: parasternal, apical, subxiphoid, and suprasternal, and the site of leak was defined and its hemodynamic impact was quantified by continuous-wave pulsed and color Doppler. Data obtained by transthoracic view were confirmed by TEE and the evaluation was performed by 3D TEE and 3D color Doppler. This allowed visualization of the entire prosthetic valve from both sides, determining defect site, number, morphology and size. Figure 1 and 2 show two cases of aortic and mitral PVL closure, respectively.

Paravalvular leak was defined as the presence of a regurgitation jet originating between the outer margin of the prosthetic ring and the surrounding tissue. Regurgitation severity was defined according to the parameters established by the American Society of Echocardiography. (19)

Paravalvular leak location is based on the adaptation of the surgical visualization modality of the mitral or aortic valve from the left atrium or aorta respectively, using the clock position as reference from the surgeon's perspective; (18, 20-22) moreover, the echocardiogram allowed guiding the procedure or complementing fluoroscopy during closure, accompanying catheter insertion, the passage of the guidewire through the defect, and the deployment and release of the closure device, to ensure the absence of interference with prosthetic valve function and the absence of flow through the device. This type of interventions is made mostly without the use of contrast.

A coronary angiography was performed to rule out associated coronary artery disease. The angiographic studies were conducted by a specialized interventional cardiologist with a Philips Clarity-Allura or Philips Allura transducer.

Technical success was defined when the device was cor-

rectly implanted without producing interference with prosthesis functioning and with decreased valvular regurgitation ≥ 1 degree. Clinical success was considered for FC improvement ≥ 1 degree and hemolysis parameter recovery, allowing the patient to remain free from transfusions after closure and during follow-up. (12-15)

30-day and long-term in-hospital clinical and echocardiographic follow-up

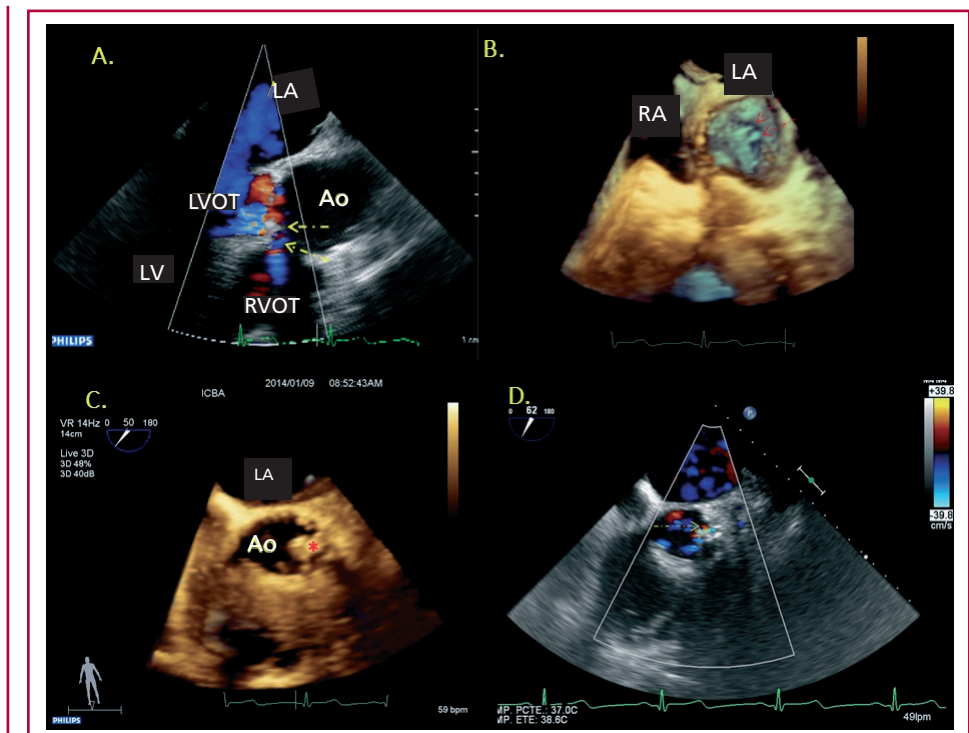
Mortality related to the procedure, cardiovascular death, neurological events (transient ischemic attack and stroke), acute myocardial infarction, cardiac tamponade, vascular access complications, such as bleeding requiring intervention and/or red blood cell transfusions and urgent conversion to conventional surgery were assessed. All patients were followed-up in an outpatient basis by a clinical cardiologist. The FC and/or associated symptoms and events assessed in the acute stage were determined. Furthermore, new transthoracic Doppler echocardiographies were performed to assess the parameters described above

Aortic paravalvular leak closure technique.

In the hemodynamics laboratory, all patients receive general anesthesia or deep sedation with neuroleptoanalgesia by an anesthesiologist to guide the procedure with 3D TEE. (23-29) Retrograde access is used for this type of closure, generally by the femoral artery or occasionally by brachial or transapical access. In all cases, 100 IU/kg heparin was administered intravenously or arterially. Initially, a spinal catheter is introduced over a 0.035" hydrophilic guidewire; subsequently, it crosses the defect into the left ventricle and is exchanged by a high support guidewire (0.035" or 0.038" of 260 mm, with a 1 cm long straight flexible tip that can be curved) for greater stability and support, through which the device delivery sheath slides, to be presented in the defect.

The correct positioning is confirmed by TEE and radi-

Fig. 1. Frequency of statin use at discharge in acute coronary syndrome patients according to year of discharge (chi-squared test for linear trend p-value <0.01)



oscopy, assessing the absence of residual flow without interference with the heart valve prosthesis or other structures, deciding its final deployment.

Mitral paravalvular leak closure technique.

In this case the transapical retrograde access is mostly used, by surgical thoracotomy or occasionally by anterograde transseptal, retrograde femoral or retrograde transaortic puncture. To achieve this access, a thoracic multislice CT scan is performed to locate the best access site to the cardiac apex, and with TEE guidance, a left anterior minithoracotomy is performed. The puncture is performed under echocardiography and fluoroscopy guidance, placing a 6 or 7 Fr Cordis-Brite-tip introducer.

Next, a JR or spinal catheter is inserted over a 0.035" hydrophilic guidewire crossing the defect into the left atrium guided by 3D TEE. Subsequently, the guidewire is exchanged by one with higher support. In case of multiple defects it is possible to leave a 0.014" or 0.035" guidewire in the contiguous defects to facilitate the closure once the device is implanted in the major defect. Then the device release sheath and the occluder device are advanced into the left atrium, while for its guidance and release the process is similar to that used for the transfemoral access. (30, 31) (Figure 3)

Type of devices

Nitinol vascular occluder devices are mainly used as they adapt to different anatomies and are relatively conformable. The Amplatzer® Vascular Plug type II presents sizes ranging from 3 to 22 mm, 6 to 18 mm length and usually a 5 Fr delivery system; however, the Amplatzer® Vascular Plug III is the first device specifically designed for this type of closure with very promising results. It consists of a compact mesh, thinner fibers, elliptical shape adapting better to the semi-lunar morphology very common in these defects generating

greater contact surface favoring a more efficient sealing. The Amplatzer® Vascular Plug IV is much smaller and is delivered by 5F systems. As it has no retention disc it tends to prolapse at the moment of positioning in the defect.

Statistical analysis

Continuous variables are expressed as mean±standard deviation and median±interquartile range according to their distribution, and categorical variables are expressed as percentages. Student's t-test for paired data and the Wilcoxon test for the analysis of continuous variables were used as appropriate. A two-tailed p value <0.05 was considered statistically significant. The statistical analysis was performed using SPSS 21.0 statistical package.

Ethical considerations

The study was carried out in compliance with the patient's right to protection of personal data.

RESULTS

Nine consecutive patients selected for closure of 13 PVL located in the aortic or mitral valves were assessed from August 2010 to October 2015. In 3 patients, more than one device was employed to achieve successful regurgitation reduction due to the presence of more than one defect. In 5 patients in whom the location of the leak was perimitral, the transapical approach was used and in the aortic cases, the retrograde transaortic approach was selected. In all patients, coronary angiography showed no significant coronary lesions.

A total of 13 occluder devices were implanted, mainly of the type Amplatzer St Jude Medical Models II and III. This approach achieved effective PVL

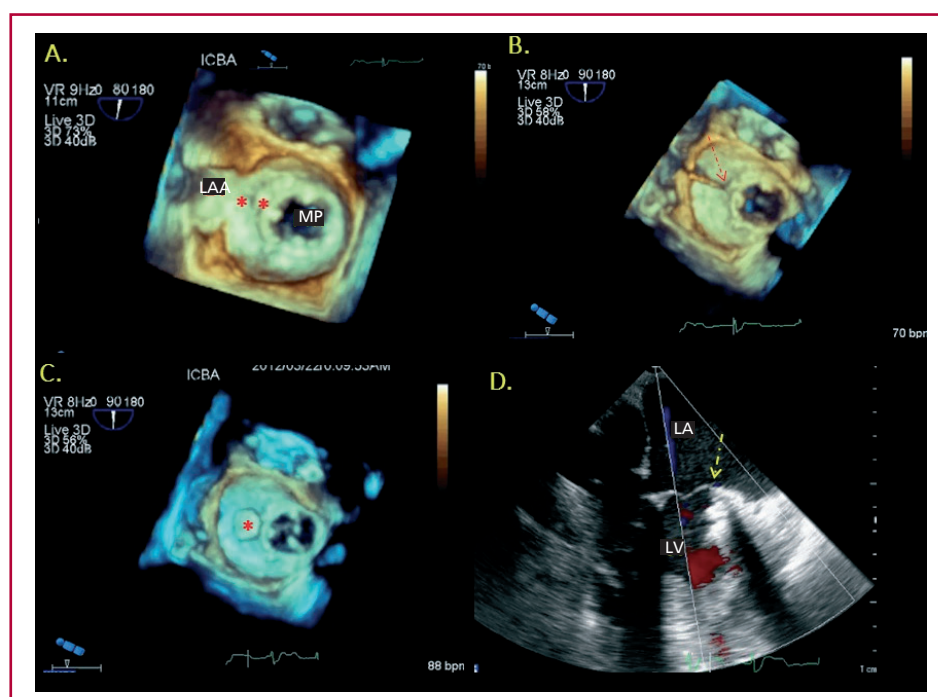
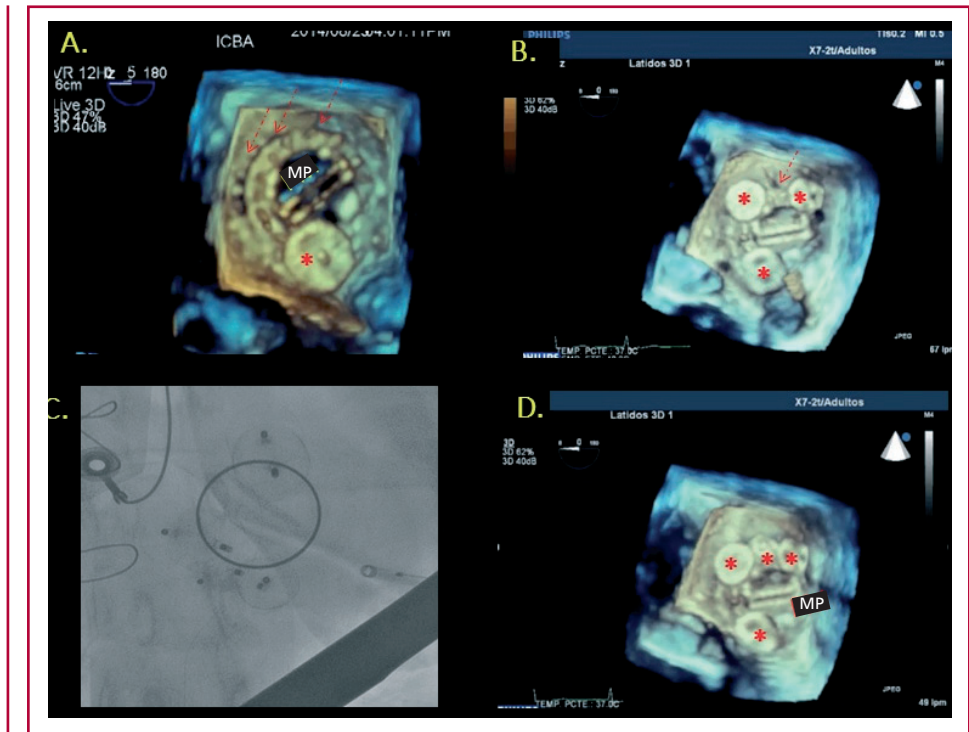


Fig. 2. Distribution of type of drugs used according to year of discharge. **A.** Global distribution. **B.** Private health care system. **C.** Public health care system.

Fig. 3. A. Distribution of doses of atorvastatin, simvastatin and rosuvastatin according to year of discharge. B. Frequency of low, moderate and high-intensity use of statin therapy according to year of discharge.



closure with a technical success rate of 100% and no evidence of significant regurgitation by 3D TEE and angiography (Table 2). Closure of the femoral access was performed by manual compression and in the case of transapical access by surgical compression, without complications.

During hospitalization, a transthoracic echocardiography showed absence of device mobilization, embolization, flow through the device, interference with valve prosthesis and other cardiac structures, and without the presence of pericardial effusion. Among the echocardiographic parameters, residual valve failure was minimal and pulmonary systolic pressure changed from 54.2 ± 11 to 36.1 ± 8 mmHg ($p=0.03$) after closure.

No patient required emergency surgery during hospitalization and no in-hospital deaths, stroke or myocardial infarctions were recorded. Two patients, in whom transapical access was used, had bleeding requiring red blood cell transfusion, with favorable outcome.

No major cardiovascular events were recorded at 30 days, and the symptoms of all patients improved significantly; they are currently in FC I, with a clinical success rate of 100%. The case presenting hemolytic anemia normalized laboratory values. In the mid-term follow-up (22 months, interquartile range 3-44), all patients survived and maintained the FC, echocardiographic parameters and laboratory values.

DISCUSSION

Currently, PVL closure can be performed percutane-

Table 2. Procedural characteristics (n = 9)

Access	4
Femoral, n	5
Transapical, n	
Technique used	4
Retrograde aortic, n	5
Transapical, n	Plug II 10
Device size, mm	Plug II 12
	Plug II 12 / Plug IV 5
	Occluder 6
	Plug III 14
	Plug III 16/14/10
	Plug II 10/12
	Plug III 12
	Plug II 9
Post-procedural valvular regurgitation	
Mild, %	100
Moderate, %	0
Severe, %	0

ously in most cases. Although reports in the literature are scarce and disparate, generally from small samples, they are mostly made in high complexity centers, since they represent a challenge for the interaction of different cardiovascular specialties such as imaging experts, cardiac surgeons and interventionalists specialized in structural pathology.

The procedures are often long and require expertise in a variety of complex catheter techniques. The selection of the access site depends primarily on the PVL location and the operators' experience. In our experience we have chosen the retrograde transaortic access in aortic cases and the transapical access in mitral cases, due to the medial and superolateral location of leaks.

One of the main findings of the study is the high percentage of clinical and technical success, similar to reports of reference centers worldwide, as reflected by Ruiz et al. (86%) and Sorajja et al. (81%) (12, 32)

This high success rate can be explained by different reasons. In this series, all procedures were guided with 3D TEE. In this regard, the participation of echocardiography specialists, widely familiar with the visualization of these defects and the contribution of real time 3D images, play a true central role because it guides the operator in different stages. This success rate was similar for both mechanical and biological aortic and mitral prostheses, differing from some reports that describe a lower success rate in the mitral position. (10) Series analysis revealed survival of all intervened patients during follow-up, perhaps due to successful closure of all leaks and to the absence of residual regurgitation, that is superior to that described in the literature available so far. (4-7)

No vascular complications, death, myocardial infarction or stroke at 30 days and at follow-up were reported. The absence of complications does not reflect the complexity of this type of intervention or of the patients included in the study. It is only a small sample of highly selected patients. In all cases, symptomatic improvement was maintained at the long-term follow up, most likely due to the absence of residual valve regurgitation, indicating that percutaneous PVL closure may be a completely valid alternative to valve replacement surgery, with a marked and sustained FC improvement.

Advances in the field of structural heart disease have contributed to the adaptation of many technical and interventional progresses, in an attempt to further improve the success of percutaneous techniques, while the risk of complications is reduced. In terms of future perspectives, the possibility of having multimodality images, such as the fusion of angiography, computed tomography and 3D echocardiography, together with the use of intracardiac ultrasound will probably determine the access and the real-time leak exact location and thus guide its closure. (4, 21-35) The use of alternative access techniques, such as direct transapical puncture, will provide the possibility of further progress in this percutaneous intervention.

Limitations

The results analyzed correspond to a small cohort of highly selected patients with mid-term follow up. The irrelevant rate of events in the series did not allow comparisons between subgroups of patients.

CONCLUSIONS

Percutaneous PVL closure is a safe and effective procedure, enabling a substantial improvement of valve regurgitation and FC with a low rate of adverse events. The success of the procedure has an intimate relationship with a clear understanding of the anatomy, location and leak morphology with appropriate real-time imaging and with training of a multidisciplinary team in preprocedural, intraprocedural and postprocedural management.

These data support percutaneous repair as part of a comprehensive treatment strategy for the management of this challenging group of patients, who usually entail a high surgical risk.

Conflicts of interest

None declared. (See authors' conflicts of interest forms in the website/Supplementary material).

REFERENCES

1. Ionescu A, Fraser AG, Butchart EG. Prevalence and clinical significance of incidental paraprosthetic valvar regurgitation: a prospective study using transoesophageal echocardiography. *Heart* 2003;89:1316-21. <http://doi.org/ff77gz>
2. Hammermeister K, Sethi GK, Henderson WG, Grover FL, Oprian C, Rahimtoola SH, et al. Outcomes 15 years after valve replacement with a mechanical versus a bioprosthetic valve: Final report of the veterans affairs randomized trial. *J Am Coll Cardiol* 2000;36:1152-8. <http://doi.org/cdzzvw>
3. Krishnaswamy A, Tuzcu EM, Kapadia SR. Percutaneous paravalvular leak closure. *Interventional Cardiology Review* 2013;9:44-8. <http://doi.org/bqmm>
4. Bartel T, Müller S. Intraprocedural guidance: which imaging technique ranks highest and which one is complementary for closing paravalvular leaks? *Cardiovasc Diagn Ther* 2014;4:277-8.
5. Echevarria JR, Bernal JM, Rabasa JM, Morales D, Revilla Y, Revuelta JM, et al. Reoperation for bioprosthetic valve dysfunction. A decade of clinical experience. *Eur J Cardiothorac Surg* 1991;5:523-6. <http://doi.org/bwt4jk>
6. Emery RW, Krogh CC, Mc Adams S, Emery AM, Holter AR, et al. Long-term follow up of patients undergoing reoperative surgery with aortic or mitral valve replacement using a St Jude medical prosthesis. *J Heart Valve Dis* 2010;19:473-84.
7. Álvarez JA, Alonso JL, Leiva GA, Baglioni P, Fernández Recalde ML, Rivas C y cols. Aplicaciones no convencionales de dispositivos endovasculares en cardiopatías estructurales adquiridas. *Rev Argent Cardiol* 2013;81:159-63. <http://doi.org/bqmm>
8. Shapira Y, Hirsch R, Kornowski R, Hasdai D, Assali A, Vaturi M, et al. Percutaneous closure of perivalvular leaks with Amplatzer occluders: feasibility, safety, and shortterm results. *J Heart Valve Dis* 2007;16:305-13.
9. Sorajja P, Cabalka AK, Hagler DJ, Rihal CS. Long-term follow-up of percutaneous repair of paravalvular prosthetic regurgitation. *J Am Coll Cardiol* 2011;58:2218-24. <http://doi.org/ftqwb>
10. Sorajja P, Cabalka AK, Hagler DJ, Rihal CS. Percutaneous repair of paravalvular prosthetic regurgitation: acute and 30-day outcomes in 115 patients. *Circ Cardiovasc Interv* 2011;4:314-21. <http://doi.org/c3hdgx>
11. Alonso-Briales JH, Muñoz-García AJ, Jiménez-Navarro MF, Domínguez-Franco AJ, Melero-Tejedor JM, Rodríguez-Bailón I, et al. Utilización de los dispositivos Amplatzer para el cierre de fugas perivalvulares. *Rev Esp Cardiol* 2009;62:442-6. <http://doi.org/fps5k9>
12. Ruiz CE, Jelnin V, Kronzon I, Dudi Y, Del Valle-Fernández R, Einhorn BN, et al. Clinical outcomes in patients undergoing percutaneous closure of periprosthetic paravalvular leaks. *J Am Coll Cardiol* 2011;58:2210-7. <http://doi.org/bh5vm8>

13. Charanjit S, Rihal, Sorajja P, Booker JD, Hagler DJ, Cabalka AK, et al. Principles of percutaneous paravalvular leak closure. *J Am Coll Cardiol Interv* 2012;5:121-30. <http://doi.org/bqmp>
14. Sánchez-Recalde A, Moreno R, Galeote G, Jiménez-Valero S, Calvo L, Hernández Sevillano J, et al. Evolución inmediata y a medio plazo de las dehiscencias paravalvulares cerradas percutáneamente. *Rev Esp Cardiol* 2014;67:615-23. <http://doi.org/f2skk5>
15. Cruz-González I, Rama-Merchan JC, Arribas-Jiménez A, Rodríguez-Collado J, Martín-Moreiras J, Cascon-Bueno M, et al. Cierre percutáneo de fugas peri protésicas con el dispositivo Amplatzer Vascular Plug III: resultados inmediatos y a corto plazo. *Rev Esp Cardiol* 2014;67:608-14. <http://doi.org/f2pz76>
16. Sorajja P, Cabalka AK, Hagler DJ, Rihal CS. The learning curve in percutaneous repair of paravalvular prosthetic regurgitation. *J Am Coll Cardiol Interv* 2014;7:521-9. <http://doi.org/bqmq>
17. Roques F, Nashef SA, Michel P, Gauducheau E, de Vincentiis C, Baudet E, et al. Analysis of the EuroSCORE multinational database of 19030 patients. *Eur J Cardiothorac Surg* 1999;15:816-22. <http://doi.org/fhjhx8>
18. De Cicco G, Russo C, Moreo A. Mitral valve periprosthetic leakage: anatomical observations in 135 patients from a multicentre study. *Eur J Cardiothorac Surg* 2006;30:887-91. <http://doi.org/b8nrv3>
19. Zoghbi WA, Chair F, Chambers JB, Dumesnil JG, Foster E, Gottdiener JS, et al. Recommendations for Evaluation of Prosthetic Valves With Echocardiography and Doppler Ultrasound A Report From the American Society of Echocardiography's Guidelines and Standards Committee and the Task Force on Prosthetic Valves, Developed in Conjunction With the American College of Cardiology Cardiovascular Imaging Committee, Cardiac Imaging Committee of the American Heart Association, the European Association of Echocardiography, a registered branch of the European Society of Cardiology, the Japanese Society of Echocardiography and the Canadian Society of Echocardiography, Endorsed by the American College of Cardiology Foundation, American Heart Association, European Association of Echocardiography, a registered branch of the European Society of Cardiology, the Japanese Society of Echocardiography, and Canadian Society of Echocardiography. *J Am Soc Echocardiogr* 2009;22:975-1014. <http://doi.org/dzfv8k>
20. De Cicco G, Lorusso R, Colli A. Aortic valve periprosthetic leakage: anatomic observations and surgical results. *Ann Thorac Surg* 2005;79:1480-5. <http://doi.org/d43msd>
21. Ruiz CE, Cohen H, Del Valle-Fernandez R, Jelnin V, Perk G, Kronzon I, et al. Closure of prosthetic paravalvular leaks: a long way to go. *Eur Heart J Suppl* 2010;12:E52-E62. <http://doi.org/djf5rt>
22. Vivancos-Delgado R, Gómez de Diego JJ, Río Aguilar-Torres, Forteza-Alberti JF. Novedades en técnicas de imagen cardiaca. *Rev Esp Cardiol* 2011;64:30-41. <http://doi.org/fmw22x>
23. Hein R, Wunderlich N, Robertson G, Wilson N, Sievert H. Catheter closure of paravalvular leak. *EuroInterv* 2006;2:318-25.
24. García E, Sandoval J, Unzué L, Hernández-Antolin R, Almería C, Macaya C. Paravalvular leaks: mechanisms, diagnosis and management. *EuroIntervention* 2012;8:Q41-Q52. <http://doi.org/bqmr>
25. Gafoor S, Steinberg DH, Franke J, Bertog S, Vaskelyte L, Hofmann I, et al. Tools and Techniques - Clinical: Paravalvular leak closure. *EuroIntervention* 2014;9:1359-63. <http://doi.org/bqms>
26. Buellesfeld L, Meier B. Treatment of paravalvular leaks through interventional techniques. *Multimedia manual of cardiothoracic surgery.mmcts*. <http://mmcts.oxfordjournals.org/content/2011/0924/mmcts.2010.004895.full.pdf>
27. Kim MS, Casserly IP, Garcia JA, Klein AJ, Salcedo EE, Carroll JD. Percutaneous transcatheter closure of prosthetic mitral paravalvular leaks. Are we there yet? *J Am Coll Cardiol Interv* 2009;2:81-90. <http://doi.org/b2m87b>
28. Pate GE, Thompson CR, Munt BI, Webb JG. Techniques for percutaneous closure of prosthetic paravalvular leaks. *Catheter Cardiovasc Interv* 2006;67:158-66. <http://doi.org/d35jb3>
29. Klinger C, Eiros R, Isasti G, Einhorn B, Jelnin V, Cohen H, et al. Review of surgical prosthetic paravalvular leaks: diagnosis and catheter-based closure. *Eur Heart J* 2013;34:638-49. <http://doi.org/bqmt>
30. Larman M, Lasa G, San Martín JC, Gaviria K. Vía transapical como alternativa para el cierre del leak paravalvular. *Rev Esp Cardiol* 2011;64:75-83. <http://doi.org/dpgkkm>
31. Nau G, Albertal M, Vrancic M, Ronderos R, Sánchez G, Navia D, et al. Cierre percutáneo de fuga paravalvular mitral. *Rev Argent Cardiol* 2011;79:537-40.
32. Sorajja P, Cabalka AK, Hagler DJ, Reeder GS, Chandrasekaran K, Cetta F, et al. Successful percutaneous repair of paravalvular prosthetic regurgitation. *Catheter Cardiovasc Interv* 2007;70:815-23. <http://doi.org/d6td9k>
33. Klinger C, Ruiz C. Reconsideración del cierre percutáneo de la fuga paravalvular: ¿hacia dónde vamos ahora? *Rev Esp Cardiol* 2014;67:593-6. <http://doi.org/f2r9jk>
34. Hoffmayer KS, Pharm D, Zellner C, Kwan DM, Konety S, Foster E, et al. Closure of a para-valvular aortic leak with the use of 2 AMPLATZER devices and real-time 2- and 3-dimensional transesophageal echocardiography. *Tex Heart Inst J* 2011;38:81-4.
35. Klinger C, Cruz-González I, Ruiz CE. Presente y futuro de la ecocardiografía intracardiaca para guiar las intervenciones en cardiopatía estructural. *Rev Esp Cardiol* 2012;65:791-4. <http://doi.org/f2fmkb>