

Coronary-Pulmonary Artery Fistula as Cause of Acute Coronary Syndrome

Coronary artery fistula (CAF) is a rare congenital or acquired condition that involves an abnormal communication between a coronary artery and either a cardiac chamber or a great vessel around the heart. (1) Coronary-pulmonary artery fistulas account for 15-30% of CAF cases. In general, larger CAFs present clinical relevance, focusing mainly on the mechanism of coronary steal phenomenon, and causing angina and dyspnea associated to coronary steal and, rarely, to myocardial dysfunction. (3)

We report the case of a 55-year-old woman with a history of arterial hypertension, poor adherence to treatment, and no history of surgeries, cardiac events or trauma. She was admitted to the emergency room with a 24-hour history of moderate, pulsatile, holo-cranial headache, and moderate to severe oppressive retrosternal pain radiating to the shoulder and left arm, with dyspnea and generalized pallor. Physical examination revealed blood pressure 200/70 mmHg, breathing rate 20 cpm, and arterial oxygen saturation 94%. ECG showed sinus rhythm, 58 bpm, negative T waves in anteroseptal and high lateral wall, and absence of Q waves (Figure 1A). Laboratory data: Troponin T 82 ng/mL, CK-MB 9.34 ng/mL. Transthoracic Doppler echocardiography revealed left ventricular ejection fraction (LVEF) 60%, apical hypokinesis, grade I diastolic dysfunction, absence of pericardial effusion or intracavitary thrombi, and no pulmonary hypertension (PH).

The patient was referred to the Interventional

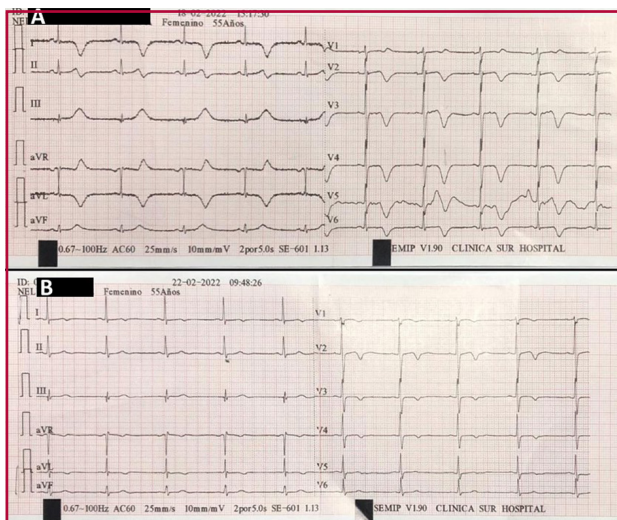


Fig. 1. A. ECG on admission. Negative T waves in leads DI, aVL, V2- V6 (high lateral and anteroseptal wall). **B.** ECG at discharge. Improved left ventricular repolarization in leads DI, aVL and V1-V6.

Cardiology Department with a diagnosis of non-ST segment elevation acute myocardial infarction (AMI). Coronary angiography (CAG) targeted no lesions in epicardial coronary arteries and a coronary fistula originating from the distal segment of the right coronary artery (RCA) and draining into the right pulmonary circulation, a medium-sized vessel with a caliber of 2.5 mm in the proximal portion (Figure 2 A and B). Left ventriculography showed apical and inferoapical hypokinesis and slightly decreased contractile reserve.

Percutaneous embolization beyond the first curve of the fistula using 3 coils (4.0 mm x 7 cm, 5.0 mm x 10 cm and 3 mm x 9 cm) was successfully performed without complications, confirmed by the final angiography (Figure 2 C). The patient was discharged asymptomatic and with ECG improvement on the third day of hospitalization (Figure 1 B). ECG showed preserved systolic function, normal pulmonary pressure, and no wall contractility abnormalities.

The first reported case of a coronary artery fistula was in 1865 by Krause; it is mostly a congenital vascular malformation of relatively low incidence —0.3% of congenital heart disease—, but it is the most common hemodynamically significant congenital defect of the coronary arteries, comprising the 13–14% of the angiographically recognized coronary artery anomalies. (3, 4) Most CAFs originate from the RCA or anterior descending artery, and drain into low-pressure structures including right-sided chambers, pulmonary artery, superior vena cava, and coronary sinus. (4, 5)

CAF is usually small, asymptomatic, and are diagnosed incidentally on imaging tests. CAFs often close spontaneously; however, larger or multiple CAFs —depending on the degree of severity of the shunt or coronary sequestration— are associated with symptoms such as fatigue, dyspnea, palpitations and/or angina. (2, 6) Possible complications include volume overload, myocardial hypertrophy and congestive heart failure, or myocardial ischemia/infarction in the absence of coronary atherosclerosis, arrhythmias, PH, endocarditis or rupture. (1, 2)

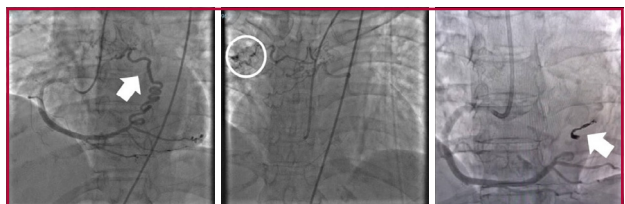


Fig. 2. A & B. Angiography of the right coronary artery (RCA). Dominant artery without lesions; medium-sized fistula of distal origin and tortuous trajectory (*white arrow*) draining into the pulmonary circulation (*white circle*). **C.** Final angiography of the RCA. Closure of the coronary-pulmonary artery fistula, coils (*white arrow*), and patent RCA in all branches with no evidence of dissection, thrombus or embolization.

In our case, we concluded that angina was due to increased myocardial oxygen requirement secondary to high blood pressure. Mechanically, we considered that anteroapical myocardial ischemia was caused by a steal effect to the anterior descending artery circulation through the septal branches, since the fistula originated from the distal segment of the RCA. Our classification was type-2 AMI due to elevated cardiac enzymes.

Medium-sized CAFs should be closed in symptomatic patients, while larger CAFs should be closed regardless of symptoms. (5, 6) Therapeutic strategies depend on the anatomy of the fistula, its clinical presentation and the team's experience, and a surgical or percutaneous technique can be chosen, considering the risk and feasibility of the procedure. (2, 5) Despite the recommendation of surgical ligation over coil embolization, (2) following an individualized approach was beneficial.

In conclusion, CAF is the most common congenital anomaly of hemodynamically significant coronary arteries. We recommend treating all medium-sized CAFs. Over the years, this entity may lead to further growth of the artery, resulting in further concomitant cardiac disorders and therapeutic complexity.

Conflicts of interest

None declared.

(See authors' conflict of interests forms on the web/Additional material.)

Ethical considerations

Not applicable.

**Carlos I. Soledispa¹, Marco Larrea¹,
Stephanie S. Alberca¹, Ariel Zelaya¹,
Klinton Sanango¹**

¹ Clínica Sur Hospital, Department of Interventional Cardiology (Guayaquil, Ecuador).

Carlos I. Soledispa – ISAC/ Clínica Sur Hospital, Department of Interventional Cardiology (Guayaquil, Ecuador). Av. Febres Cordero Rivadeneyra y Alfredo Adum - 091910, Guayaquil, Ecuador.

Address for reprints:

E-mail: carisosu@gmail.com

REFERENCES

1. Urmeneta Ulloa J, Molina Borao I, Ochoa Rea ME, Sánchez-Insa E. Percutaneous closure of coronary artery fistula before lung transplantation. *Arch Bronconeumol* 2017;53:520–1. <https://doi.org/10.1016/j.arbres.2017.02.013>
2. Sulemankhil I, Mohamed AH, Gilani SA. Coronary-Pulmonary Artery Fistula Repair With Coil Embolization: A Single Center Experience. *Cureus*.2022;14:e28407. <https://doi.org/10.7759/cureus.28407>
3. Buccheri D, Dendramis G, Piraino D, Chirco PR, Carità P, Paleologo C, et al. Coronary artery fistulas as a cause of angina: How to manage these patients? *Cardiovascular Revascularization Medicine [Internet]*. 2015;16:306–9. <https://doi.org/10.1016/j.carrev.2015.04.011>
4. Gowda RM, Vasavada BC, Khan IA. Coronary artery fistulas: Clinical and therapeutic considerations. *Int J Cardiol* 2006;107:7–10. <https://doi.org/10.1016/j.ijcard.2005.01.067>
5. Al-Hijji M, el Sabbagh A, el Hajj S, AlKhouli M, el Sabawi B, Cabalka A, et al. Coronary Artery Fistulas: Indications, Techniques, Outcomes, and Complications of Transcatheter Fistula Closure. *JACC Cardiovasc Interv [Internet]*. 2021;14:1393-406. <https://doi.org/10.1016/j.jcin.2021.02.044>
6. Buccheri D, Chirco PR, Geraci S, Caramanno G, Cortese B. Coronary Artery Fistulae: Anatomy, Diagnosis and Management Strategies. *Heart Lung Circ* 2018;27:940–51. <https://doi.org/10.1016/j.hlc.2017.07.014>

Rev Argent Cardiol 2023;91:150-151.
<http://dx.doi.org/10.7775/rac.v91.i2.20618>

Inflammatory Spondyloarthropathy Presenting as a Sole Manifestation of Left Atrial Myxoma

Cardiac tumors are rare, with an incidence of 0.002%. They may originate from the pericardium or myocardium, and are primary or secondary, the latter being 20 times more common. (1)

Primary cardiac neoplasms are infrequent, representing 0.25%. Most of them (75%) are benign and include myxomas, rhabdomyomas, fibromas, and lipomas. (2)

Cardiac myxomas represent the most common benign cardiac tumor. They are found in the left atrium (75%), right atrium (20%), or ventricles (5%). Clinically, myxomas may occur in asymptomatic individuals and are detected incidentally, or may cause symptoms usually related to its mobility, size, and location within the heart. In general, the symptomatic triad includes systemic (fever, weight loss, fatigue) or cardiac symptoms (arrhythmias, mitral or tricuspid regurgitation due to interference with valve coaptation, pericarditis, dyspnea, syncope), and pulmonary and/or systemic embolic phenomena. (2) While these are the most common manifestations, unusual forms of presentation have also been described.

Doppler echocardiography is the method of choice to diagnose and determine its characteristics and hemodynamic impact.

The clinical case of a left atrial myxoma with an unusual presentation is described below.

We report the case of a dyslipidemic, ex-smoker 61-year-old woman with no cardiovascular history, consulting for a several-month history of sacroiliac arthralgia; laboratory tests revealed elevated erythrocyte sedimentation rate (84 mm/h) and C-reactive protein (6.2 mg/L), and no other abnormalities.

After evaluation by the Rheumatology Department, diagnosis was inflammatory spondyloarthropathy with persistently elevated inflammatory markers not meeting the criteria for

rheumatic disease; the positron emission tomography (PET) scan revealed a single tumor in the left atrium (Figure 1).

Doppler echocardiography showed a rounded, heterogeneous, sessile left atrial mass attached to the interatrial septum, with wide anarchic movement, and in non-invasive contact with the right upper pulmonary vein. This mass did not interfere with the opening and closing of the mitral valve (Figure 2).

CT scan revealed a 30 x 22 mm heterogeneous left atrial mass attached to the interatrial septum, with

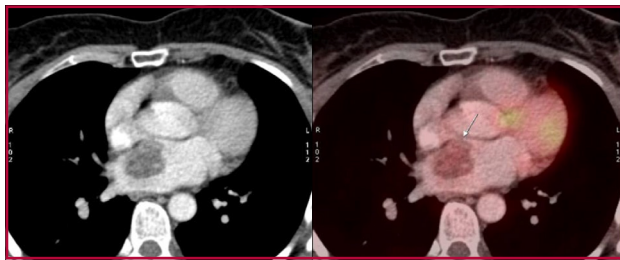


Fig. 1. PET showing hypodense left atrial mass with moderate metabolic activity.

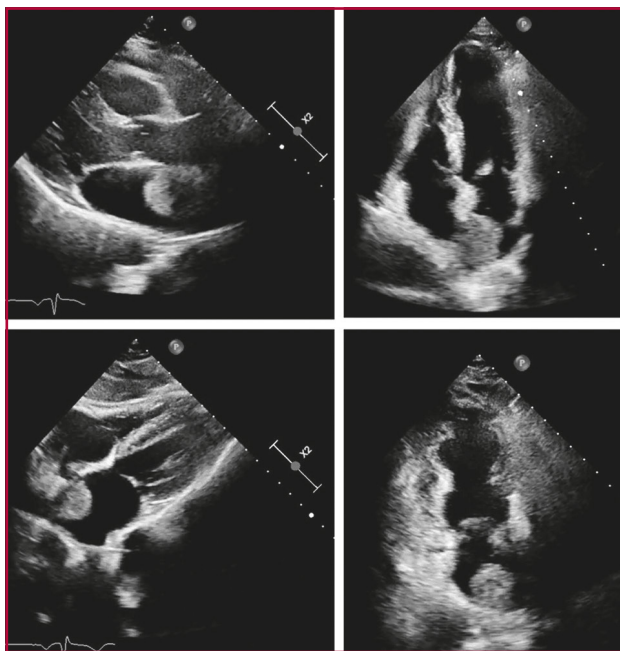


Fig. 2. Doppler echocardiography views showing a rounded, heterogeneous, left atrial mass attached to the interatrial septum.

regular borders, enhanced after intravenous contrast injection, and no evidence of invasion of the pulmonary veins. The result was interpreted as a possible atrial myxoma, and surgical resection was performed using a transeptal approach; a 5 cm tumor was resected without complications, and a biopsy was sent to Pathology.

Results revealed proliferation of perivascular spindle cells without atypia, in streaks and in a lax stroma, with signs of old and recent hemorrhage, scant fibrous tissue and myocytes, consistent with myxoma.

After surgical resection, follow-up showed improvement of joint symptoms until their disappearance and normalization of inflammatory markers.

Myxomas are the most common benign cardiac tumors, usually found in older women, (2) as was the case described here.

They are most commonly found in the left atrium (75%), as a sessile or pedunculated intracavitary mass, attached by a stalk to the interatrial septum.

Clinical manifestations are related to their cardiac location, size, and mobility. The most common symptomatic triad includes intracardiac obstruction, embolism, and systemic symptoms.

According to a French series of 112 cases, heart failure secondary to mitral valve obstruction was present in 67% of the patients, followed by cerebral emboli in 29%, and 34% with general symptoms such as fever, weight loss or symptoms resembling connective tissue disease. (3)

Intracardiac obstruction often occurs in pedunculated left atrial myxoma protruding to the left ventricle and causing mitral valve coaptation deficit and subsequent regurgitation. While uncommon, myxomas found in the right atrium may protrude into the tricuspid valve and cause regurgitation. In both cases, they can occur with heart failure or syncope. (3)

Emboli are more common in papillary myxomas, as they are less solid and become more fragile with anarchic movement. The site of the emboli depends on the location of the tumor. Left atrial myxomas have the potential for embolism to the central nervous system, resulting in stroke or amaurosis. The involvement of coronary, renal or lower limb arteries is uncommon. (4)

Constitutional symptoms may appear as connective tissue disorders, with poor general condition, weight loss, anorexia, and fever. These symptoms are more common in women than in men, and in right atrial myxomas. (4)

It is believed that extracardiac manifestations are often caused by embolic phenomena and inflammation due to the intrinsic secretion of cytokines. (5) Polymyalgia rheumatica—the manifestation that motivated our patient's consultation—is uncommon. Polymyalgia rheumatica is characterized by pain in the proximal muscles and increased serum levels of inflammatory markers. It is also one of the most common diseases in young adults and affects women more frequently than men (ratio 3:1). (6)

Doppler echocardiography is essential for the diagnosis of myxomas, and to define location, size, and complications. Both cardiac magnetic resonance imaging and cardiac multislice computed tomography provide additional information for decision making.

Myxoma needs surgical excision to reduce the risk of embolization. While the rate of recurrence is low, follow-up Doppler echocardiography is recommended. (4)

In the case reported, our patient debuted with rheumatologic manifestations with persistently elevated inflammatory markers; left atrial myxoma was incidentally found after several diagnostic tests.

Undoubtedly, myxoma remains a challenging entity to diagnose. The fact that they are typically asymptomatic or present with nonspecific symptoms makes it a non-suspected entity, mostly diagnosed incidentally. It is vital to be aware of the possible cardiovascular and systemic manifestations to suspect, diagnose and treat myxomas in a timely manner.

Conflicts of interest

None declared.

(See authors' conflicts of interest forms on the website/ Supplementary material).

Sources of funding: None.

Ethical considerations

Not applicable.

**Esperanza Raimundo, Roberto Freue,
Fernando Piccinini^{MTSAC}, Florencia Castro,
Martín Vivas, Pablo Elissamburu^{MTSAC}**

REFERENCES

1. El Sabbagh A, Al-Hijji MA, Thaden JJ, Pislaru SV, Pislaru C, Pellikka PA, et al. Cardiac Myxoma: The Great Mimicker. *JACC Cardiovasc Imaging*. 2017;10:203-6. <https://doi.org/10.1016/j.jcmg.2016.06.018>.
2. Tyebally S, Chen D, Bhattacharyya S, Mughrabi A, Hussain Z, Manisty C, et al. Cardiac Tumors: JACC CardioOncology State-of-the-Art Review. *JACC CardioOncol*. 2020;2:293-311. <https://doi.org/10.1016/j.jacc.2020.05.009>.
3. Pinede L, Duhaut P, Loire R. Clinical presentation of left atrial cardiac myxoma. A series of 112 consecutive cases. *Medicine (Baltimore)*. 2001;80:159-72. <https://doi.org/10.1097/00005792-200105000-00002>.
4. Islam AKMM. Cardiac myxomas: A narrative review. *World J Cardiol*. 2022;14:206-19. <https://doi.org/10.4330/wjcv.14.i4.206>.
5. Macias E, Nieman E, Yomogida K, Petrucci O, Javidan C, Baszisz K, et al. Rare presentation of an atrial myxoma in an adolescent patient: a case report and literature review. *BMC Pediatr*. 2018;18:373. <https://doi.org/10.1186/s12887-018-1313-6>.
6. Mano Y, Yoshizawa A, Itabashi Y, Ohki T, Takahashi T, Mori M, et al. Left atrial myxoma detected after an initial diagnosis of polymyalgia rheumatica. *Intern Med* 2014;53:441-4. <https://doi.org/10.2169/internalmedicine.53.1300>.

Rev Argent Cardiol 2023;91:151-153.

<http://dx.doi.org/10.7775/rac.v91.i2.20623>

Endovascular Treatment of Pulmonary Vein Stenosis After Atrial Fibrillation Catheter Ablation

Radiofrequency catheter ablation with pulmonary vein isolation for treatment of atrial fibrillation (AF) is a minimally invasive procedure with low rate of complications. One complication is pulmonary vein stenosis, with an incidence between 0.3 and 3.4%, but associated with high morbidity. (1-3) Symptoms of pulmonary vein stenosis include dyspnea, cough, hemoptysis, and chest pain. (4) We report a case of hemoptysis secondary to pulmonary vein stenosis after radiofrequency catheter ablation, treated with angioplasty and stent implantation.

A 42-year-old male patient with a history of radiofrequency catheter ablation of the pulmonary veins, performed in another center, and community-acquired pneumonia which was hard to treat despite the use of different antibiotic regimes, presented to the emergency department of our institution 5 months after the procedure with intermittent hemoptysis and pain in the left hemithorax.

On admission, the patient was hemodynamically stable, without fever and with no signs of heart failure. The laboratory tests showed: hematocrit 37%; white blood cell count 5490/mm³, 229 300 platelets/mm³, erythrocyte sedimentation rate 25 mm/h, and high-sensitivity C-reactive protein level 10.6 mg/L. As acute pulmonary embolism (PE) was suspected, the patient underwent chest computed angiotomography, which was negative for PE but showed areas of ground-glass opacification, with a tendency to consolidation, that were diffusely distributed in the left lung upper lobe.

The patient was clinically stable and was discharged with empiric treatment for suspected atypical pneumonia and was followed up in an outpatient basis. Because of the recent history of AF ablation and the pattern evidenced in the chest computed tomography, we decided to perform cardiac computed angiotomography to evaluate the pulmonary veins which had not been correctly visualized in the angiography requested to rule out PE. The scan showed stenosis of the left superior pulmonary vein (LSPV), with a diameter of 8.4 mm × 17 mm in length, pronounced narrowing in flute beak appearance, and critical luminal reduction with a trajectory of about 16 mm until reaching the patent intraparenchymal portion (Figure 1A). The other pulmonary veins were patent with no signs of stenosis.

In the presence of a patient with hemoptysis and symptoms of persistent pneumonia and stenosis of the LSPV, we decided to perform angioplasty of the pulmonary vein with stent implantation. A transesophageal echocardiogram (TEE) was performed before the procedure, which demonstrated increased velocities (peak velocity 2.4 m/s, peak gradient 23 mm Hg) in the vein, confirming the diagnosis (Figure 1B). Transseptal puncture was carried out through a right femoral venous access and under TEE guidance. A selective venography confirmed LSPV stenosis (Figure 2A). Then, coronary balloon catheters with increasing diameters were advanced for pre-dilation. A conventional stent with high radial strength (Herculink 7.0 × 18 mm) was implanted, with adequate angiographic results (Figure 2B). Pressures and velocities decreased in TEE (peak velocity 1.3 m/s, maximum gradient 7 mm Hg).

The patient was discharged 24 hours later, on anticoagulation with rivaroxaban 15 mg/d and antiplatelet therapy with clopidogrel 75 mg/d. At 3-month follow-up, dyspnea, cough and pain in the left side of the chest has disappeared.

Pulmonary vein stenosis after radiofrequency catheter ablation is a rare and underdiagnosed complication because symptoms can be mistaken for other conditions as pneumonia, asthma, and PE, among others. (4) The proper diagnosis of this condition is of utmost importance, as delayed diagnosis can lead to total occlusion of the pulmonary vein, resulting in pulmonary infarction and massive hemoptysis. Magnetic angiores-

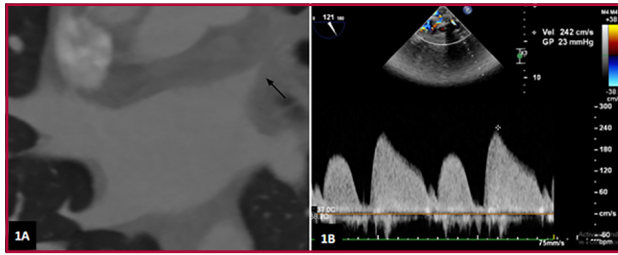


Fig. 1. A. Computed angiogram showing stenosis of the left superior pulmonary vein (*arrow*). **B.** Left superior pulmonary vein velocity measured by transesophageal echocardiography.

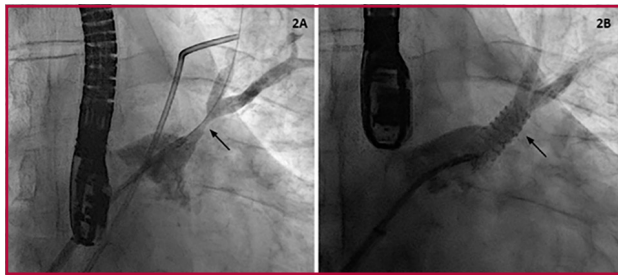


Fig. 2. A. Venography demonstrating stenosis of the left superior pulmonary vein (*arrow*). **B.** Venography after stent implantation (*arrow*) in the left superior pulmonary vein.

onance and computed angiogram are the most accurate diagnostic methods for detecting pulmonary vein stenosis. The severity of stenosis is defined by the percentage of lumen involved and is classified as mild (<50%), moderate (50%-70%) and severe (>70%). The development of symptoms is usually associated with severe stenosis or total occlusions, which can sometimes be asymptomatic. Transesophageal echocardiography is a very useful diagnostic method to guide the procedure, since it provides information on the structure of the left atrium, optimizes manipulation of materials as guide wires and balloon catheters during the procedure, and adds the evaluation of pulmonary veins flow and gradients for the diagnosis of stenosis and for evaluating treatment effectiveness. (5) In this case, we used the same procedure to provide diagnosis, guide transseptal puncture (which is ideally inferior and anterior for better orientation to the LSPV), measure velocities after the procedure, and rule out complications as pericardial effusion.

Treatment with angioplasty is intended to relieve venous pressure and improve perfusion of the affected lung. Compared to balloon angioplasty, stenting is associated with a lower rate of restenosis, especially when large stents (10 mm or more) are used. (5,6) Stent size is defined before the procedure by computed angiogram and during the procedure by angiogram, since the use of stents larger than the vein could lead to rupture and cardiac tamponade. Other treatments include lobectomy in patients with clinically significant pulmonary vein occlusion or stenosis in whom angioplasty has failed. (5)

We report this case of hemoptysis, dyspnea and pain secondary to pulmonary vein stenosis that was successfully treated with angioplasty and stent implantation. The recognition of this condition, its timely diagnosis and adequate treatment is of utmost importance to reduce patient morbidity.

Conflicts of interest

None declared.

(See authors' conflicts of interest forms on the website/ Supplementary material).

Ethical considerations

Not applicable.

**Juan I. Damonte¹, Ezequiel Lillo²,
Mariano Falconi², Santiago Sanchez Bustamante²,
Carla Agatiello, Ignacio M. Seropian¹**

¹ Department of Interventional Cardiology,
Institute of Cardiovascular Medicine,
Hospital Italiano de Buenos Aires, Argentina

² Department of Cardiology,
Institute of Cardiovascular Medicine,
Hospital Italiano de Buenos Aires, Argentina

Address for reprints:

Dr. Ignacio M. Seropian,

ignacio.seropian@hospitalitaliano.org.ar

REFERENCES

1. Correction to: Severe Pulmonary Vein Stenosis Resulting From Ablation for Atrial Fibrillation: Presentation, Management, and Clinical Outcomes. *Circulation* 2017;135(18):e1016. <https://doi.org/10.1161/CIR.0000000000000494>
2. Cappato R, Calkins H, Chen S-A, et al. Updated worldwide survey on the methods, efficacy, and safety of catheter ablation for human atrial fibrillation. *Circ Arrhythm Electrophysiol* 2010;3:32-8. <https://doi.org/10.1161/CIRCEP.109.859116>
3. Saad EB, Rossillo A, Saad CP, et al. Pulmonary vein stenosis after radiofrequency ablation of atrial fibrillation: functional characterization, evolution, and influence of the ablation strategy. *Circulation* 2003;108:3102-7. <https://doi.org/10.1161/01.CIR.000104569.96907.7F>
4. Fender EA, Widmer RJ, Hodge DO, Packer DL, Holmes DR Jr. Assessment and Management of Pulmonary Vein Occlusion After Atrial Fibrillation Ablation. *JACC Cardiovasc Interv* 2018;11:1633-9. <https://doi.org/10.1016/j.jcin.2018.05.020>
5. Calkins H, Brugada J, Packer DL, et al. HRS/EHRA/ECAS expert consensus statement on catheter and surgical ablation of atrial fibrillation: recommendations for personnel, policy, procedures and follow-up. A report of the Heart Rhythm Society (HRS) Task Force on Catheter and Surgical Ablation of Atrial Fibrillation developed in partnership with the European Heart Rhythm Association (EHRA) and the European Cardiac Arrhythmia Society (ECAS); in collaboration with the American College of Cardiology (ACC), American Heart Association (AHA), and the Society of Thoracic Surgeons (STS). Endorsed and approved by the governing bodies of the American College of Cardiology, the American Heart Association, the European Cardiac Arrhythmia Society, the European Heart Rhythm Association, the Society of Thoracic Surgeons, and the Heart Rhythm Society. *Europace* 2007;9(6):335-79. <https://doi.org/10.1093/europace/eum120>
6. Xuan Z, Liu B, Ci M, Wang Z, Fan Y. Hemoptysis secondary to pulmonary vein stenosis after radiofrequency ablation for atrial fibrillation: A case report and literature review. *J Interv Med* 2020;3:98-100. <https://doi.org/10.1016/j.jimed.2020.03.008>

Transseptal Balloon Atrial Septostomy in Patients with Advanced Pulmonary Arterial Hypertension and Systemic Lupus Erythematosus

We report the case of a 20-year-old female patient with a diagnosis of mixed connective tissue disease in 2018 but no follow-up for the last 18 months, and with Hashimoto's thyroiditis and bronchiectasis. The patient went to the Outpatient Emergency Room for abdominal pain, nausea and diarrhea. Signs of right heart failure (edema of the lower limbs, jugular venous distention without inspiratory collapse, positive hepatojugular reflux and enlarged liver), increased intensity of the second heart sound at the expense of the pulmonic component, and systolic murmur in the tricuspid focus were detected on admission. Initial diagnostic tests included an ECG showing signs of overload of the right chambers and complete right bundle branch block, and a chest X-ray with enlarged second right pulmonary arch and normal cardiothoracic ratio. Doppler echocardiography revealed enlargement of the right chambers, severe right ventricular dysfunction, severe tricuspid regurgitation with peak regurgitation velocity > 4.5 meters per second (m/s), pulmonary artery systolic pressure (PSP) 105 mmHg, mean pulmonary artery pressure (mPAP) 55 mmHg, and mild pericardial effusion (Figure 1). Right heart catheterization confirmed the diagnosis of severe pulmonary arterial hypertension (PAH) with mean right atrial pressure 11 mmHg, mPAP 63 mmHg, pulmonary wedge pressure 10 mmHg, pulmonary vascular resistance (PVR) 21 Wood units (WU), transpulmonary and diastolic gradients of 53 mmHg and 43 mmHg respectively, cardiac output (CO) 3.20 L/min, cardiac index (CI) 2.6 L/min/m², systolic volume index (SVI) 23 ml/beats/m², mixed venous saturation 65%, and arterial saturation 97%. Due to marked right ventricular failure, the patient was started on continuous intravenous infusion of furosemide with no positive response, inotropic support with high-dose milrinone that was later switched to levosimendan 0.1 ug/kg/min, and vasopressor support with intermediate doses of noradrenaline. The patient progressed unfavorably, with low cardiac output and severe right ventricular failure. Given that immediate access to parenteral prostanoids was not possible, transseptal balloon septostomy was performed (5 mm fenestration) successfully (Figure 2). The patient's clinical condition improved, with early referral to a tertiary care center for pre-transplant evaluation and continuous intravenous epoprostenol infusion—increasing doses up to 12 ng/kg/min—after weaning and discontinuation of inotropic drugs, and administration of ambrisentan 10 mg and tadalafil 10 mg, which were well tolerated. Follow-up Doppler echocardiography showed moderate enlargement of the right chambers, PSP 70 mmHg, and 0.9 mm loss of atrial septal continuity (Figure 3). Cardiac catheterization showed decreased mPAP and PVR and improved CO and CI (43 mmHg,

7.3 UW, 4.8 l/min and 3.6 l/min/m², respectively). After evaluation, the Rheumatology Department confirmed the diagnosis of systemic lupus erythematosus by clinical and immunological criteria, and class II lupus nephritis by renal biopsy.

The prevalence of PAH in connective tissue disease (CTD) is high, mainly in scleroderma and also in systemic lupus erythematosus, with a value ranging from 0.5 to 17.5%, depending on the diagnostic method used. (1) This entity continues to present high morbidity and mortality despite the evidence observed with specific drug therapies, which is high compared to idiopathic PAH (1-year survival in CTE-PAH 86% vs 93% in idiopathic PAH). (2) Patients not responding to maximal combination therapy, including parenteral prostanoids, should be referred for double lung transplant. (3) However, many patients with PAH are not candidates for transplantation, or the wait-

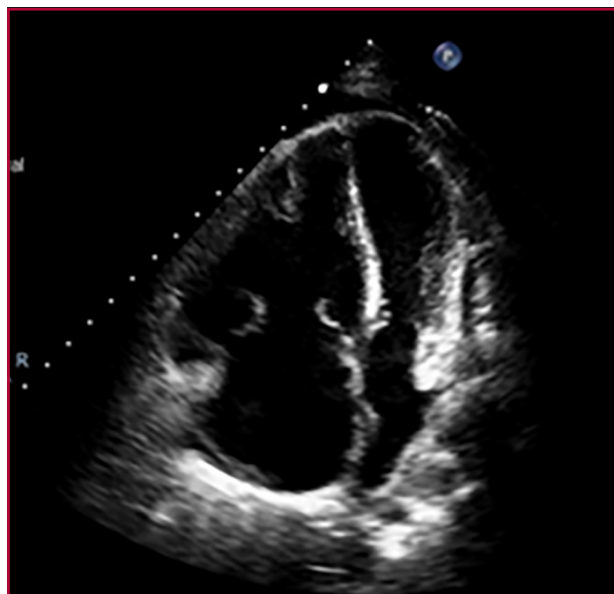

Fig. 1. Doppler echocardiography. Apical 4-chamber view showing marked enlargement of the right chambers, displacement of the ventricular septum, reduction in left ventricular diameter, and severe tricuspid regurgitation.

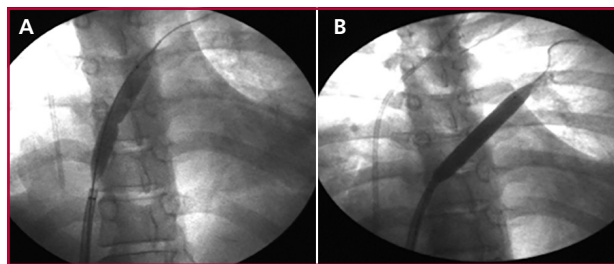


Fig. 2. Transseptal balloon septostomy. Balloon dilatation is performed reaching a maximum diameter of 5 mm under fluoroscopic guidance. **A:** Balloon inflation on guide wire centered in the atrial septum. **B:** Total balloon inflation.

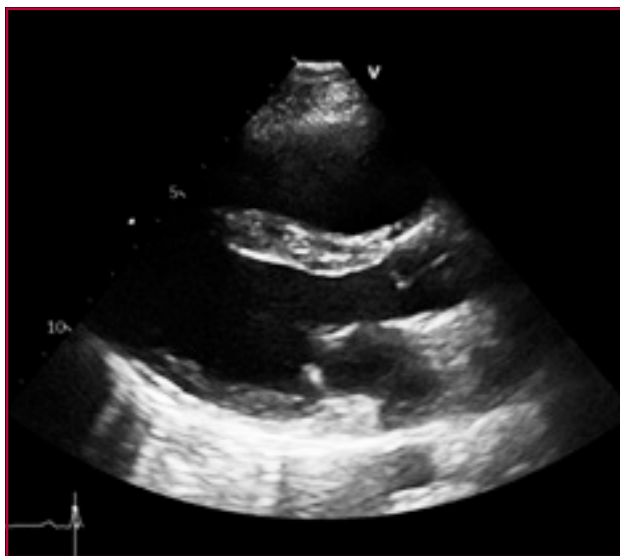


Fig. 3. Long axis parasternal view showing progressive improvement of the right ventricular diameter, reduction of compression to the left ventricle and ventricular septal hypertrophy.

ing list time is too long and patients die before being transplanted. For this reason, transeptal septostomy should be considered in patients who are on the waiting list for double lung transplant, in those who do not respond to the maximum therapeutic regimen or when it is unavailable or not tolerated. (4) It should be noted that this procedure is contraindicated in patients with arterial oxygen saturation < 90%, right atrial pressure > 20 mmHg and hemoglobin value < 12 mg/dL, and should be performed in referral centers. Several studies have reported improvement in symptoms and hemodynamics after septostomy, allowing decompression of the right heart with increased left ventricular pre-load and systemic oxygen saturation without complications associated with the procedure in highly experienced centers. (5)

Recently, a meta-analysis of 6 studies with 204 patients observed a reduction in right atrial pressure ($p < 0.001$), an increase in cardiac index ($p < 0.001$) and left atrial pressure ($p < 0.001$), but with significant reduction in oxygen saturation and 48-hour, and 30-day mortality rates of 4.8% and 14.6%, respectively. (6)

These data suggest that atrial septostomy is an invasive and relatively safe procedure in experienced centers and should only be indicated in patients with advanced severe PAH as a bridge to transplantation or when there is no response to the triple regimen with parenteral prostanoids, or when drug therapy is unavailable.

Conflicts of interest

None declared.

(See authors' conflicts of interest forms on the website/ Supplementary material).

Ethical considerations

Not applicable.

**Guillermina Sorasio^{MTSAC, 1}, Carola Zambrano^{MTSAC, 1},
Susana Taboada¹, Fernando Di Tomasso¹,
Aldo Peruso⁵, Enrique Domine¹,
Ignacio Bluro^{MTSAC, 2}**

¹ Pulmonary Hypertension Unit,

² Coronary Care Unit,

³ Department of Doppler Echocardiography,

⁴ Electrophysiology Service,

⁵ Department of Interventional Cardiology,

⁶ Chief of Cardiology.

⁷ Pulmonary Hypertension, Hospital Italiano.

Department of Cardiology - Hospital Rivadavia. Buenos Aires.
Argentina. Hospital Italiano de Buenos Aires.

Address for reprints: guillerminasorasio@gmail.com

REFERENCES

1. Tselios K, Gladman D, Urowitz M. Systemic lupus erythematosus and pulmonary arterial hypertension: links, risks, and management strategies. *Open Access Rheumatol* 2017;9:1-9 <https://doi.org/10.2147/OARRR.S123549>
2. Chung L, Liu J, Parsons L, Hassoun P, McGoon M, Badesch D, et al. Characterization of connective tissue disease-associated pulmonary arterial hypertension from REVEAL: identifying systemic sclerosis as a unique phenotype. *Chest*.2010;138:1383-94. <https://doi.org/10.1378/chest.10-0260>
3. Stacel T, Latos M, Urlik M, Necki M, Antonczyk R, Hrapkowicz T, et al. Interventional and Surgical Treatments for Pulmonary Arterial Hypertension. *J. Clin. Med* 2021;10:3326. <https://doi.org/10.3390/jcm10153326>
4. Velázquez I, Albarrán A, Jiménez C, García J, Martín R y Escribano P. Septostomía auricular en el tratamiento de la hipertensión arterial pulmonar grave del adulto. *Rev Esp Cardiol* 2016;69:78-81. <https://doi.org/10.1016/j.recesp.2015.09.011>
5. Chiu JS, Zuckerman WA, Turner ME, Richmond ME, Kerstein D, Krishnan U, et al. Balloon atrial septostomy in pulmonary arterial hypertension: effect on survival and associated outcomes. *J Heart Lung Transplant*. 2015;34:376-80. <https://doi.org/10.1016/j.healun.2015.01.004>
6. Khan M, Memon M, Amin E, Yamani N, Khan S, Vincent M, et al. Use of Balloon Atrial Septostomy in Patients with Advanced Pulmonary Arterial Hypertension. A Systematic Review and Meta-Analysis. *Chest* 2019;156:53-63. <https://doi.org/10.1016/j.ijcard.2019.02.051>

Rev Argent Cardiol 2023;91:155-156.

<http://dx.doi.org/10.7775/rac.v91.i2.20622>

Portopulmonary Syndrome Following Liver Transplantation: A Rare Etiology of Dyspnea that Should Not Be Ignored

We report the case of a 54-year-old male patient with a history of liver transplantation in 2019 due to alcoholic cirrhosis. A right heart catheterization was performed as part of the pretransplant evaluation, due to moderate pulmonary hypertension (PH) on echocardiography, confirming that PH was associated with high pulmonary blood flow and low pulmonary resistances.

Three months after transplantation, the patient came to our emergency room for progressive dyspnea and signs of pulmonary and peripheral congestion, but stable with nasal cannula oxygen therapy. ECG

showed new-onset right bundle branch block. Laboratory tests revealed elevated D-dimer (2980 ug/mL) and NT-proBNP (10 500 ng/L) levels. A computed angiogram of the pulmonary arteries was performed to rule out the initial suspicion of pulmonary thromboembolism (Figure 1), targeting no thrombi, but revealing marked pulmonary artery dilation, suggestive of significant PH. Given the poor response to diuretics, the patient was evaluated by the Cardiology Department at our center. Transthoracic echocardiography (TTE) (Figure 2) showed marked right ventricular (RV) enlargement and dysfunction, with an estimated pulmonary artery systolic pressure (PASP) of 120 mmHg, suggestive of severe PH.

Due to rapid clinical worsening —mainly breathlessness— with increased tachypnea and signs of heart failure, the patient was referred to the Coronary Care Unit to start intravenous therapy with higher doses of dobutamine and furosemide (1 g in continuous infusion). Evacuative paracentesis for symptomatic management of ascites was performed, and Doppler ultrasound confirmed proper functioning of the liver graft. Differential diagnosis was broad, considering that the patient had a history of cirrhosis, dyspnea, and acute heart failure.

Portopulmonary hypertension (PoPH) syndrome is included within group 1 PH, (1) and accounts for 10% of the total cases of this entity. PoPH is defined as pulmonary arterial hypertension (PAH) associated with portal hypertension. (2) It occurs in 1-2% of these patients; (1) in fact, in the REVEAL Registry—a multicenter, observational study on 3000 PAH patients—, the prevalence of PoPH was 5%, more common in women and in autoimmune cirrhosis. (3) Severity is determined by mean pulmonary pressure (mPAP) value; therefore, it is defined as mild PoPH in patients with mPAP < 35 mmHg, and as severe PoPH in cases of mPAP > 45 mmHg. The pathophysiology of PoPH is not known; however, the theory with the most significant impact states that it is due to an imbalance of vasoconstrictor mediators and vasodilators. While most

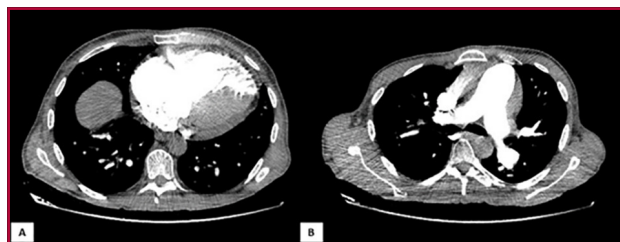


Fig. 1. Computed angiogram of the pulmonary arteries. Axial planes at the level of ventricular cardiac chambers (A) and at the level of the great vessels outflow tracts and bifurcation of the pulmonary artery (B). No intravascular filling defects in the pulmonary artery or images suggestive of thrombus (B) are observed. RV enlargement is of note, with a right / left ventricle ratio >1 (A). RV: right ventricle.

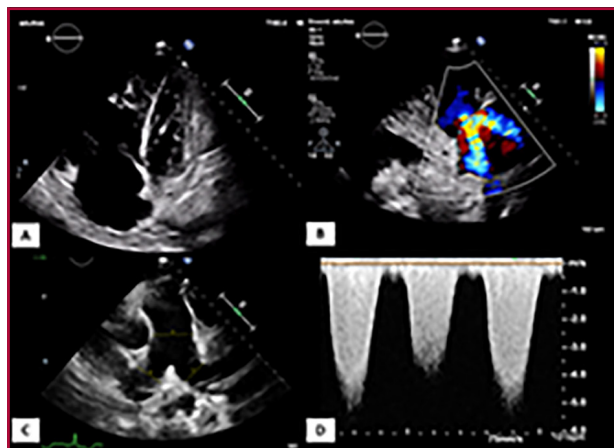


Fig. 2. Transthoracic echocardiography on admission. Apical 4-chamber planes (A) modified parasternal long axis over RV (B), parasternal short axis at the level of great vessels (C) and continuous Doppler over tricuspid regurgitation flow (D). Figure (A) shows severe RV enlargement and dysfunction, with severe functional tricuspid regurgitation (B). Enlargement of the pulmonary artery. The RV-RA gradient of tricuspid regurgitation by Doppler is 120 mmHg (D), suggestive of severe PH. PH: pulmonary hypertension. RA: right atrium. RV: right ventricle

patients are asymptomatic, dyspnea on exertion is the most common symptom, as was the case in our patient.

Current European guidelines (1) recommend starting the diagnostic evaluation with TTE, so that, in patients with indirect data of PH (peak tricuspid regurgitation velocity > 2.8 m/s, RV enlargement, pulmonary artery or inferior vena cava enlargement) or with other risk factors, right heart catheterization would be indicated, as was the case in our patient. The study revealed severe precapillary PAH: mPAP 57 mmHg, wedge pressure 11 mmHg, elevated transpulmonary gradient 46 mmHg, and pulmonary vascular resistance (PVR) 14.5 Wood units (WU).

Current hemodynamic diagnostic criteria for PAH include: mPAP > 20 mmHg at rest, wedge pressure ≤ 15 mmHg, and PVR > 2 WU. (1)

The ultimate criterion for diagnostic certainty of PoPH would be to confirm portal hypertension by clinical signs; in case of doubt, venous catheterization to measure the hepatic venous pressure gradient is suggested. (4)

As this criterion was unmet in our patient, diagnosis was "probable portopulmonary syndrome", although isolated cases of de novo diagnosis of PoPH within the first 6 months following transplantation have been described in the literature.

It is an entity with poor prognosis: in the absence of therapy, PoPH has been associated with a 5-year survival rate of 14%; (2) however, a 51% improvement in 5-year survival rate under medical treatment and 81% with liver transplantation have been reported. (5)

While positive outcomes with the medical treatment of PAH have been reported, most studies are

not aimed at PoPH patients (except for the PORTICO trial, which showed positive hemodynamic outcomes with macitentan, or the PATENT-1 trial, (6) which included a small PoPH population under riociguat treatment, with positive functional outcomes); in any case, this therapy has shown positive hemodynamic and functional effects, but no effect on survival rates.

Current guidelines recommend triple combination therapy of endothelin receptor antagonist, phosphodiesterase-5 inhibitor and prostacyclin receptor agonist (Class IIa recommendation) in high-risk patients, as was the case reported here. (1) Our patient was started on epoprostenol, sildenafil and macitentan, showing a slow but progressive improvement, followed by withdrawal of inotropes.

Typically, liver transplantation is contraindicated in these patients due to high perioperative morbidity and mortality, and would only be recommended in patients with liver disease per se requiring transplantation; it was not discussed in the case of our patient since his graft function was normal. Guidelines recommend initiation of PAH therapies in patients with mPAP > 35 mmHg candidates for transplantation; (3) however, it is contraindicated in severe PoPH not improving with medical treatment, since perioperative mortality in patients with mPAP > 45 mmHg is close to 100%.

One month after admission, the patient was discharged on triple therapy and home hospitalization. Follow-up TTE at 6 months showed normal RV function; PAH medication was progressively withdrawn.

Differential diagnosis should consider PH associated to high pulmonary blood flow (with normal PVR and no need to initiate a specific therapy) and hepatopulmonary syndrome (typically presenting without PH, characterized by arteriovenous shunts in the pulmonary circulation, and causing hypoxemia, orthodeoxia and platypnea; liver transplantation is the treatment of choice in severe cases).

Less common entities—which should be considered in patients with a history of liver disease—include cirrhotic cardiomyopathy, other typical causes of heart failure, and extracardiac causes of dyspnea—common in this patient profile—such as anemia, ascites, or hydrothorax.

In conclusion, dyspnea in patients with a history of liver disease has been a challenge for cardiologists, not only because of the wide range of diagnoses to be

assessed, but also because of its complex hemodynamic profile. Portopulmonary syndrome is a rare entity. While its standard definition refers to patients with portal hypertension, this entity is currently being described in already transplanted patients—particularly early, in the first 6 months post-transplantation—as in the case reported here; therefore, we must always take it into account, given its poor prognosis and the absence of a specific treatment *per se*.

Conflicts of interest

None declared.

(See authors' conflicts of interest forms on the website/Supplementary material).

Ethical considerations

Not applicable.

**Ana Ruiz Rodríguez¹, Uxue Idiazábal Rodríguez¹,
Iñigo Pereiro Lili¹**

¹ Department of Cardiology,
Hospital Universitario de Basurto
(Bilbao, Spain).

Address for reprints: Ana Ruiz Rodríguez
Email: anarrmo@gmail.com

REFERENCES

- Humbert M, Kovacs G, Hoeper MM, et al. ESC/ERS Scientific Document Group. 2022 ESC/ERS Guidelines for the diagnosis and treatment of pulmonary hypertension. *Eur Heart J* 2022;43:3618-731. <https://doi.org/10.1093/eurheartj/ehac237>
- Navarro-Vergara DI, Roldan-Valadez E, Cueto-Robledo G, Jurado-Hernandez MY. Portopulmonary Hypertension: Prevalence, Clinical and Hemodynamic Features. *Curr Probl Cardiol*. 2021;46:100747. <https://doi.org/10.1016/j.cpcardiol.2020.100747>
- Krowka MJ, Miller DP, Barst RJ, Taichman D, Dweik RA, Badesch DB, et al. Portopulmonary hypertension: a report from the US-based REVEAL Registry. *Chest*. 2012;141:906-15. <https://doi.org/10.1378/chest.11-0160>
- Thomas C, et al. Portopulmonary Hypertension: From Bench to Bedside. *Front. Med*. 7:569413. <https://doi.org/10.3389/fmed.2020.569413>
- Savale L, Guimas M, Ebstein N, Fertin M, Jevnikar M, Renard S, et al. Portopulmonary hypertension in the current era of pulmonary hypertension management. *J Hepatol*. 2020;73:130-9. <https://doi.org/10.1016/j.jhep.2020.02.021>
- Cartin-Ceba R, Halank M, Ghofrani HA, Humbert M, Mattson J, Fritsch A, et al. Riociguat treatment for portopulmonary hypertension: a subgroup analysis from the PATENT-1/-2 studies. *Pulm Circ*. 2018;8:2045894018769305. <https://doi.org/10.1177/2045894018769305>

Rev Argent Cardiol 2023;91:156-158.
<http://dx.doi.org/10.7775/rac.v91.i2.20617>

