REFERENCES

1. Abdulrahman M, Al-Moghairi, Hussein S. Al-Amri. Management of retained intervention guide-wire: a literature review. Curr Cardiol Rev 2013;9:260-6. http://doi.org/bdww

2. Khonsari S, Livermore J, Mahrer P, Magnusson P. Fracture and dislodgment of floppy guidewire during percutaneous transluminal coronary angioplasty. Am J Cardiol 1986;58:855-6. http://doi.org/d4bv8t

3. Hartzler GO, Rutherford BD, McConahay DR. Retained percutaneous transluminal coronary angioplasty equipment components and their management. Am J Cardiol 1987;60:1260-4. http://doi.org/cvpq6r

4. Lotan C, Hasin Y, Stone D, Meyers S, Applebaum A, Gotsman MS. Guide wire entrapment during PTCA: a potentially dangerous complication. Cathet Cardiovascular Diagn 1987;13:309-12. http://doi.org/fsrk44

5. Vrolix M, Vanhaecke J, Piessens J, De Geest H. An unusual case of guide wire fracture during percutaneous transluminal coronary angioplasty. Cathet Cardiovasc Diagn 1988;15:99-102. http://doi.org/dg78f9

6. López-Mínguez JR, Dávila E, Doblado M, Merchán A, González R , Alonso F. Rupture and intracoronary entrapment of an angioplasty guidewire with the X-Sizer thromboatherectomy catheter during rescue angioplasty. Rev Esp Cardiol 2004;57:180-3. http://doi.org/bdwx

Rev Argent Cardiol 2016;84:359-361. http://dx.doi.org/10.7775/rac.v84.i4.7955

Primary Cardiac Leiomyosarcoma in a Pregnant Woman

We report the case of a 19-year-old woman at 34-week gestation, who was admitted to Hospital Juárez de México with tachycardia, dyspnea, and hemoptysis. In the emergency room, she was diagnosed with heart failure and acute pulmonary edema. The patient had no history of heart disease. Chest X-rays showed congestive lungs characteristic of acute pulmonary edema and two-dimensional echocardiography revealed a 40 × 47 mm tumor within the left atrium, attached to the left superior pulmonary vein drainage. The rest of the cardiac structures were normal (Figure 1). She underwent surgery, and the tumor and implantation base were completely removed. The patient and her baby had no complications despite undergoing surgery and extracorporeal circulation. The histological study revealed a highly malignant pleomorphic leiomyosarcoma. Histopathological evaluations were performed with specific muscle actin, CD 34, desmin, myoglobin, vimentin, and PS 100, which confirmed the leiomyosarcoma (Figure 2A). The patient refused chemotherapy during her pregnancy and was delivered of a son by Cesarean section 5 weeks later, without any birth defects. Once again, the patient refused chemotherapy, and one year later she was readmitted due to primary tumor of the central nervous system. She underwent surgery of a low-grade astrocytoma (Figure 2B) without association with the cardiac tumor, so both were considered primary tumors.

Her central nervous system tumor was treated with chemotherapy and surgical resection; however, the patient died due to complications associated with the neurosurgical procedure.

Primary cardiac tumors are rare, with a reported prevalence of 0.001% to 0.026% at autopsy series; the most common tumors include metastases or direct cardiac invasion originating in the breast or the lung. (1)

Angiosarcoma is the most common type among primary malignant tumors, followed by rhabdomyosarcoma, fibrosarcoma, and mesothelioma. Leiomyosarcoma is a mesenchymal tumor originating from smooth muscle cells and accounts for less than 1% of malignancies. In the heart, it is located mainly in the left atrium and pulmonary veins. (2)

It usually causes dyspnea, pericardial effusion, chest pain, atrial arrhythmias, peripheral embolism, or heart failure, and occasionally weight loss and fever. It is a highly metastatic tumor with a high recurrence rate in the same site once resection is performed. (3)

Therefore, prognosis is poor, with a mean survival rate of 6 months since diagnosis.

In general, the characterization of sarcomas can be difficult, but the use of immunohistochemical markers can provide accurate identification and differentiation, as cellularity is usually high in some areas. The nuclei of tumor cells typically elongate with a variable degree of pleomorphism; a wide frequency of mitotic figures are found and immunohistochemical staining with proliferation marker Ki-67 and stainings such as smooth muscle alpha-actin and desmin are typical –as was the case of this patient. (2)

In the treatment of cardiac tumors, the surgical option itself does not provide its complete and effective eradication because the tumor often involves a large myocardial portion leading to incomplete surgical resection or systemic dissemination. Survival rate varies from one case series to another, averaging between 17-28 months for those with complete resection, and 6 months in the case of incomplete resection. (4)

The role of adjuvant chemotherapy is still controversial. Some studies have found that conventional postoperative chemotherapy does not alter the clinical course, while other studies have reported the efficacy of combining surgery and adjuvant therapy. (1)

In conclusion, we believe this case is important because we managed to completely eradicate the malignant tumor with a timely surgical treatment, prolonging the life of the mother and her son for some time. However, a new primary tumor in the brain caused the patient's death. According to the database, this is the first case in Latin America with cardiac leiomyosarcoma in a pregnant woman.

Carlos N. Soberanis Torruco, Eder N. Flores López, Luis F. Arias Velarde, Carlos Ugarte Briones, Luis F. Covarrubias Gil, Tania Guerrero Marin

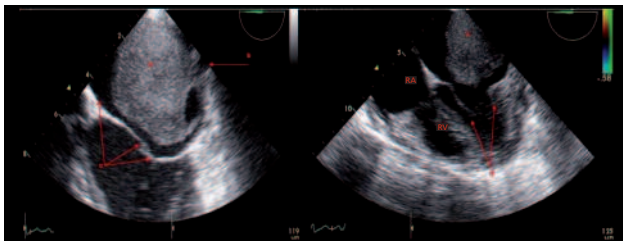

Fig. 1. Two and 4-chamber two-dimensional transthoracic echocardiography, showing left intra-atrial tumor (a), left superior pulmonary vein drainage (b), atrial contour (c) and free mitral valve (d). RA: Right atrium. RV: Right ventricle

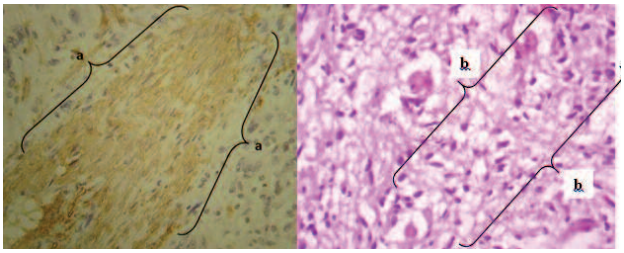

Fig. 2. A. Histopathological study with specific muscle actin; fusocellular pattern; diagnosis of cardiac leiomyosarcoma. **B.** Histological section with hematoxylin and eosin. 40 × HIP Astrocyte hipercellularity. Low-grade astrocytoma

Hospital Juárez de México – Department of Cardiology.
Ciudad de México, México
Dr. Eder Natanael Flores López - Hospital Juárez de México
Av. Instituto Politécnico Nacional Número 5160
Colonia Magdalena de las Salinas
México DF, CP: 07760 - Tel. 58257924
e-mail: dr.eder.natanael@msn.com

REFERENCES

1. Pacini D, Careddu L, Pantaleo A, Parolari A, Leone O, Daprati A, Gargiulo GD, Di Bartolomeo R. Primary malignant tumors of the heart: Outcomes of the surgical treatment. Asian Cardiovasc Thorac Ann 2015;23:645-51. http://doi.org/bjm8

2. Winther C, Timmermans-Wielenga V, Daugaard S, Mortensen SA, Sander K, Andersen CB. Primary cardiac tumors: a clinicopathologic evaluation of four cases. Cardiovasc Pathol 2011;20:63-7. http://doi.org/fczfp4

3. Wang JG, Cui L, Jiang T, Li YJ, Wei ZM. Primary cardiac leiomyosarcoma: an analysis of clinical characteristics and outcome patterns. Asian Cardiovasc Thorac Ann 2015;23:623-30. http://doi.org/bjm9

4. Neragi-Miandoab S, Kim J, Vlahakes GJ. Malignant tumours of the heart: a review of tumour type, diagnosis and therapy. Clin Oncol (R Coll Radiol) 2007;19:748-56. http://doi.org/fv93rc

Rev Argent Cardiol 2016;84:361-362. http://dx.doi.org/10.7775/rac.v84.i4.8939