

Longitudinal Strain at Rest Does not Predict Stress Echo Results

El strain longitudinal en reposo no predice el resultado del eco estrés

NATALIO GASTALDELLO[†], PABLO MERLO^{MTSAC}, MIGUEL AMOR^{MTSAC}, DIEGO ALASIA, MARCELA GALELLO, MARÍA ROUSSE[†], NORBERTO CASO^{MTSAC}, CRISTIAN CANIGGIA^{MTSAC}, VÍCTOR DARÚ^{MTSAC}, JORGE LOWENSTEIN^{MTSAC}

ABSTRACT

Background: Stress echo shows ischemia as a transient regional motility disorder. The subjective visual analysis which is dependent on the operator's experience has prompted the search for a semiautomatic method to mitigate this limitation and improve the reliability and reproducibility of the test. This has generated a growing interest in the introduction of two-dimensional longitudinal strain before, during and after stress echo. If useful, its assessment during the different stress stages would attenuate other limitations, such as the inability to achieve submaximal heart rate, difficult visualization of more subtle disorders and delay in image acquisition, which increases false negative results.

Objectives: The aim of this study was to assess whether longitudinal strain analysis at rest is able to predict the outcome of stress echo when there is no visual evidence of contractile disorders, and whether baseline longitudinal strain is different in patients with significant coronary artery disease compared with patients not presenting this disease (in their previous evaluation before the test).

Methods: The study compared longitudinal strain results at rest in 62 patients with positive stress echo consecutively recruited during a 12-month period, half of whom underwent coronary angiography (Group A) and the other half did not undertake this study (Group B) versus a control group (Group C) with negative test and without coronary angiography.

Results: Longitudinal strain showed no significant difference between groups A and B ($-21.8\% \pm 2.4\%$ vs. $-21.5\% \pm 2.5\%$) and neither between patients with positive test (Group A+B) versus Group C ($-21.67\% \pm 2.4\%$ vs. $-21.9\% \pm 2.8\%$).

Conclusions: Two-dimensional longitudinal strain did not predict stress echo results or the presence of significant coronary artery disease in the group of patients undergoing invasive coronary angiography.

Key words: 2D longitudinal strain - Speckle tracking - Stress echocardiography.

RESUMEN

Introducción: El eco estrés evidencia la isquemia miocárdica como un trastorno regional y transitorio de la motilidad. El análisis visual es subjetivo y depende de la experiencia del operador, lo que ha motivado la búsqueda de un método semiautomático que permita minimizar esta limitación y así mejorar la confiabilidad y reproducibilidad de la prueba. Esto ha generado creciente interés en la introducción de la medición del strain longitudinal bidimensional antes del eco estrés y durante y después de él. Su determinación en las diferentes fases de apremio, en caso de que sea útil, permitiría reducir otras limitaciones, como la imposibilidad de alcanzar la frecuencia cardíaca submáxima, la dificultad de visualizar trastornos muy sutiles y el retraso en la adquisición de las imágenes, lo que incrementa los falsos negativos.

Objetivos: Evaluar si el análisis del strain longitudinal realizado en reposo, cuando no hay evidencias de trastornos contráctiles visuales, es capaz de predecir el resultado del eco estrés y si el strain longitudinal basal es diferente en los pacientes con enfermedad coronaria significativa en comparación con los que no la presentan (en su evaluación previa al comienzo de la prueba).

Material y métodos: Se compararon los resultados del strain longitudinal en reposo en 62 pacientes con eco estrés positivo incorporados en forma consecutiva en un período de 12 meses, a la mitad de los cuales se les realizó una cinecoronariografía (Grupo A) y a la otra mitad no se le efectuó este estudio (Grupo B) versus un grupo control (Grupo C) con prueba negativa y sin cinecoronariografía.

Resultados: El strain longitudinal entre el Grupo A y el Grupo B no mostró diferencia estadística significativa ($-21,8\% \pm 2,4\%$ vs. $-21,5\% \pm 2,5\%$), como tampoco el de los pacientes con prueba positiva (Grupo A + B) versus los controles ($-21,67\% \pm 2,4\%$ vs. $21,9\% \pm 2,8\%$).

Conclusión: El strain longitudinal bidimensional no permitió predecir el resultado del eco estrés ni tampoco la presencia de enfermedad coronaria significativa en los pacientes que fueron sometidos a cinecoronariografía invasiva.

Palabras clave: Strain longitudinal 2D - Speckle tracking - Ecocardiografía de estrés

REV ARGENT CARDIOL 2016;84:330-335. <http://dx.doi.org/10.7775/rac.v84.i4.8530>

SEE RELATED ARTICLE: REV ARGENT CARDIOL 2016;84:302-303. <http://dx.doi.org/10.7775/rac.v84.i4.9201>

REV ARGENT CARDIOL 2016;84:351-354. <http://dx.doi.org/10.7775/rac.v84.i4.9062>

Received: 04/21/2016 – Accepted: 06/15/2016

Address for reprints: Natalio Gastaldello - Investigaciones Médicas - Viamonte 1871 - (1056) CABA - e-mail: ngastaldello@gmail.com

Investigaciones Médicas - Cardiac Diagnostic Unit. Buenos Aires, Argentina

^{MTSAC} Full Member of the Argentine Society of Cardiology

[†] To apply as Full Member of the Argentine Society of Cardiology

Abbreviations

2D	Two-dimensional	LAD	Left anterior descending artery
CA	Coronary angiography	LMCA	Left main coronary artery
CXA	Circumflex coronary artery	RCA	Right coronary artery
HR	Heart rate	WMSI	Wall motion score index

INTRODUCTION

Stress-echo sensitivity and specificity has made it a practical and reliable test to detect myocardial ischemia. (1) Regardless the type of stress, the echocardiographic evidence of ischemia is always the same: abnormal regional motility. (2) The visual analysis of these abnormalities requires a trained operator. (1) This operator-dependence has promoted the search for a semiautomatic method to reduce stress echo limitations and improve test accuracy. (3) Strain or myocardial deformation analysis based on two-dimensional (2D) speckle tracking allows discriminating between myocardial active and passive movements, which has resulted in a growing interest to introduce this new technique during stress echo. (3, 4) Other occasional limitations are the inability to attain submaximal HR, reducing its sensitivity. In this sense, the hypothesis of detecting subtle changes in longitudinal deformation at rest in patients with coronary stenosis has encouraged studies attributing longitudinal strain at rest the ability to predict the presence of severe and even moderate coronary artery disease and also stress echo outcome. (5-7) The discordance of these results with our daily practice prompted the present study to evaluate whether longitudinal strain at rest analysis is able to detect coronary artery disease similarly to the visual analysis of the study and to predict the result of stress echo.

METHODS

All patients referred to our laboratory with positive stress echo, without wall motion abnormalities at rest and normal ejection fraction, were consecutively included in the study during a 12-month period. Patients with left bundle branch block, absence of sinus rhythm, frequent ventricular extrasystoles, significant left ventricular hypertrophy, mild to severe left heart valve disease, history of prior revascularization, decreased ejection fraction, and patients with contractile dysfunction and/or poor 2D image quality were excluded from the study.

The control group consisted of patients with similar characteristics without ischemia during the test. The number of symptomatic patients by prior stable angina was significantly larger in the group with positive studies than in the negative controls ($p=0.0005$). The studies were performed with GE Vivid 7 and 9 ultrasound systems with 3.5 MHz phase array transducer.

Exercise stress testing was performed in semi-supine position with a cycleergometer and modified Astrand protocol, and pharmacological stress with dobutamine or dipridamol was done according to standard protocols. (8) Three, 4 and 2 chamber apical images of the baseline capture, acquired with simple focus and frame rate between 50 to 80 frames per second, were used for the analysis. Baseline longitudinal

deformation analysis was performed off-line in a workstation (GE EchoPAC PC software) with automatic functional image (AFI) technique by two operators blinded to the stress echo results.

This technique consists in manually selecting 3 endocardial points (2 basal and 1 apical) and an algorithm automatically traces 3 lines that follow the endocardial, mesocardial and epicardial borders. The region of interest and the adequate segment tracking was verified and manually modified as necessary. The time of aortic valve opening and closure was obtained from an aortic flow tracing. For the analysis of individual segments, a value $\geq -15\%$ for basal, -17% for medial and -20% for apical segments was considered normal, according to results of a previous study in our laboratory with normal healthy patients.

The extent of ischemia was evaluated according to the wall motion score index (WMSI) assessed by the intervening physician and reviewed by another operator. Demographic data, sex, age, major cardiovascular risk factors, HR and baseline blood pressure were recorded, as well as WMSI and longitudinal deformation results discriminated for each of the 16 segments, global longitudinal deformation (average of all the segments) and of each of the three theoretical coronary territories.

The four apical segments: basal and medial septal anterior, basal and medial anterior were assigned to the theoretical territory of the left anterior descending artery (LAD), and the basal and medial lateral segments were allocated to the circumflex artery (CXA) territory. The remaining segments were considered as right coronary artery (RCA) territory. Patients were contacted to request the result of the coronary angiography (CA) performed according to the decision of the treating physician.

Statistical analysis

The results of continuous variables are expressed as mean and standard deviation or median and interquartile range. Qualitative variables are expressed as frequencies and percentages. Student's *t* test, ANOVA followed by Bonferroni or a non-parametric test was used to compare quantitative variables, as appropriate. Categorical variables were compared using the chi-square test or Fisher's exact test. A *p* value <0.05 was considered statistically significant. SPSS version 18 software (SPSS Inc, 5 Chicago, IL) was used to perform statistical analyses.

Ethical considerations

The study was evaluated and approved by the institutional Research Committee. An informed consent was requested, authorized by a relative or person responsible for each patient included in the study.

RESULTS

One hundred and thirty-five patients, fulfilling the eligibility criteria entered the study between February 2013 and February 2014.

Table 1. Baseline characteristics of the control group (C) vs. groups with positive test and coronary angiography (A) and positive test without coronary angiography (B). Symptoms: Angina or equivalent symptoms as reason for the study. SBP: Baseline systolic blood pressure. CA: Coronary angiography. ns: Not significant.

	Group C (Control, n=62)	Group A (Positive patients with CA, n=31)	Group B (Positive patients without CA, n=31)	p
Age, years	64.8 ± 10	63.6 ± 9.5	65.6 ± 9.7	ns
Male sex, n (%)	38 (61%)	23 (74%)	20 (67%)	ns
Diabetes, n (%)	14 (23%)	9 (29%)	4 (13%)	ns
Hypertension, n (%)	41 (66%)	25 (80%)	23 (76%)	ns
Dyslipidemia, n (%)	30 (48%)	19 (61%)	10 (33%)	ns
Smoking, n (%)	1 (2%)	6 (9%)	4 (13%)	0.01
Former smokers, n (%)	26 (42%)	12 (39%)	9(30%9	ns
Baseline SBP, mmHg	131 ± 17	137.8 ± 19.7	137.57 ± 23.04	ns
Prior angina, n (%)	18 (29%)	22 (71%)	16 (52%)	0.0005

Eleven patients were excluded due to the impossibility of assessing longitudinal deformation in more than two segments (86% feasibility). The remaining 124 patients were divided for analysis into 3 groups: Group A, consisting of 31 patients with positive stress test and CA; Group B composed of 31 patients with positive stress test and without CA, and Group C comprising 62 control patients with negative test. Table 1 shows baseline characteristics of the different groups.

The type of stress used was exercise in 78% of cases and pharmacological with dobutamine (15%) and dipyridamole (7%) in the remaining patients.

In Group C, all exercise tests were maximal until exhaustion and the intended HR was reached in 85% of cases, while with pharmacological stress, the protocol was completed in all patients.

In Group A patients, CA showed significant left main coronary artery (LMCA) lesion in 4 patients (13%), 1-vessel coronary artery disease in 15 (48%), 2-vessel disease in 8 (26%) and 3-vessel disease in 8 patients (26%). The comparison of global longitudinal deformation between Group A and Group B did not evidence statistically significant differences (-21.8%±2.4% vs. -21.5%±2.5%) and neither that of patients with positive test (Group A+B) vs. controls (-21.67%±2.4% vs. -21.9%±2.8%) (Table 2).

In 96.7% of cases, patients with positive test, confirmed by significant lesion of the culprit vessel in the CA presented normal global longitudinal strain values at rest. Due to a question attributable to the technique (apical segments are the ones evidencing more deformation), mean longitudinal deformation in the theoretical LAD artery territory was significantly larger than in the other two territories in the three groups, but it was not different in patients with ischemia vs. Group C (-24.4%±3.1% vs. -23.6%±3%), nor in the 28 patients with ischemia in the theoretical LAD artery territory, with significant LMCA or LAD artery involvement documented by CA (-23.8%±3.2%) (Table 3).

Figure 1 describes a patient with LMCA and 3-vessel lesion and completely normal LS at rest.

Regional and global longitudinal strain analysis at rest could not discriminate patients with positive stress echo test.

Table 2. Percentage of baseline longitudinal deformation in the different groups

	Group A (n=31)	Group B (n=31)	Group C (n=62)	p
LD, %	-21.8 ±2.4	-21.5±2.5		ns
		-21.67±2.4	-21.9±2.8	ns

LD: Longitudinal deformation. ns: Not significant.

Table 3. Percentage of baseline longitudinal deformation in ischemic patients with left main coronary artery or left anterior descending artery (LAD) disease vs. non-ischemic controls

	LMCA or LAD (n=28)	Control (n=62)	p
LD, %	- 23.8±3.2	- 23.6± 3	ns

LD: Longitudinal deformation. LMCA: Left main coronary artery. LAD: Left anterior descending artery. ns: Not significant.

DISCUSSION

The request of stress echo studies is constantly increasing. However, its accuracy is still limited to the operator's experience in the subjective interpretation of wall motion abnormalities. (9, 10)

One of the tools to overcome this limitation is 2D strain or deformation based on speckle tracking. (11)

The present study was mainly focused on the analysis of longitudinal strain which depends on subendocardial fiber behavior due to their high sensitivity to ischemia. Radial deformation was not evaluated because it is a consequence of longitudinal deformation as a result of myocardial incompressibility; neither was circumferential deformation assessed as it is less reproducible and more dependent on transmural involvement. (12)

The main advantages of longitudinal deformation analysis are its simple and fast performance and interpretation and that, as it is not based on Doppler effect it is independent of the exploration angle, it can be applied to all myocardial segments and its results are validated by sonomicrometry and magnetic resonance tagging. (13, 14)

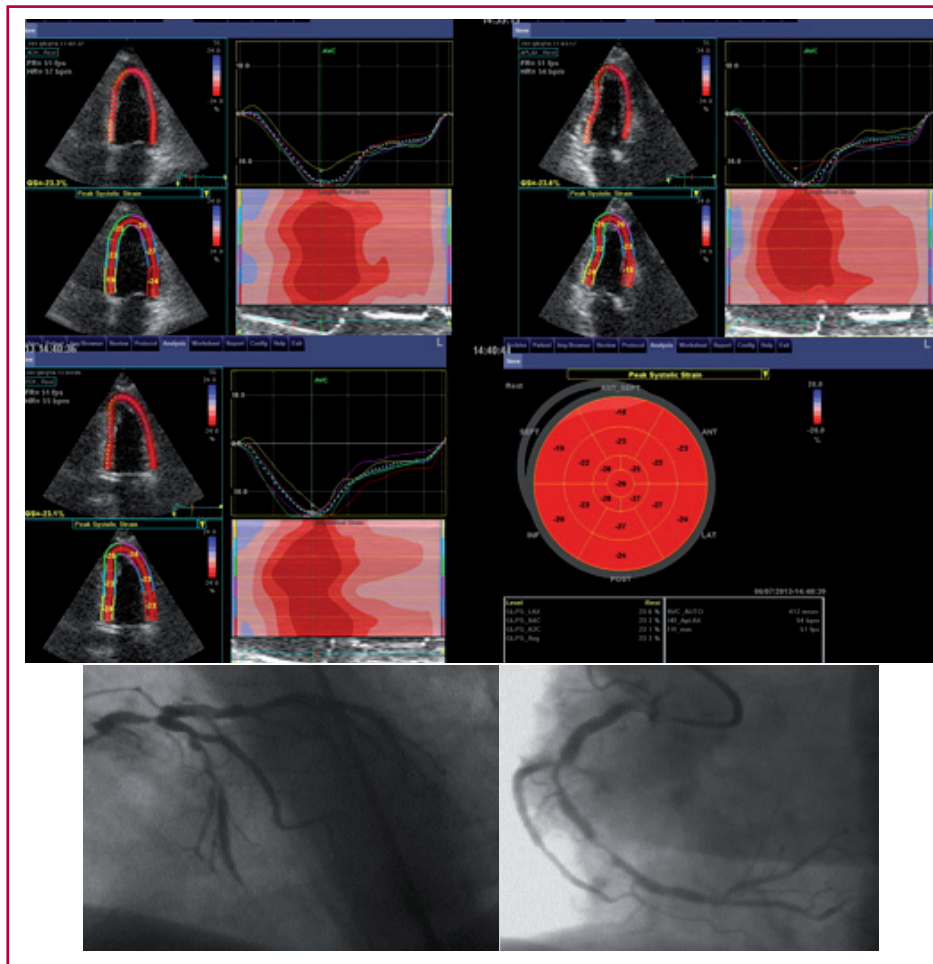


Fig. 1. Example of a patient with stable class I angina and completely normal baseline regional and global longitudinal strain, with low-load ischemia and left main coronary artery lesion and severe stenosis in the three coronary arteries (global longitudinal deformation at rest was -23.3%).

It should be acknowledged that the limitations of longitudinal strain are its absolute dependence on the quality of the ultrasonic window and that it has problems at elevated HR due to the lower temporal resolution of 2D strain compared with tissue Doppler.

In a previous study we have shown the high feasibility of 2D longitudinal deformation analysis at rest (99%) and in the immediate post-stress, before 30 seconds (97.5%). Lack of increase or decrease in longitudinal deformation of apical segments was in accordance with the presence of visually detected ischemia in 78.6% of studies, while apical longitudinal deformation increased in 96.2% of cases in which ischemia was not detected by wall motion criteria. Longitudinal strain was only reliable for segments related with the LAD artery but because a gold standard is not available, it was not possible to assess whether strain increased the accuracy of the test compared with the visual analysis. (15)

The main purpose of the present study was to evaluate whether baseline longitudinal strain prior to stress was capable of predicting its result and the presence of significant coronary artery disease.

In contrast to the available literature (5-7), the result of this study allows confirming that in our ex-

perience it is impossible to predict the stress echo outcome based on regional and global longitudinal strain results, even in very severe coronary disease cases and in symptomatic patients with multivessel disease, as for example the one shown in Figure 1.

Even though not all positive patients had control CA, the 31 patients with CA presented the same characteristics that positive patients without CA and similar ischemic response.

The difference with the mentioned studies could be attributed to the fact that our patients were completely asymptomatic 24 hours prior to the study with normal electrocardiogram, and that with the experience of having analyzed longitudinal strain in thousands of studies, we take care of all the technical details, always using simple focus and obsessively ensuring that the displacement detected by the software follows exactly the movements of the myocardial wall.

We have verified that slight changes in the “anchorage” of the most basal segments may turn a relatively low result into an absolutely normal one. The work of David Montgomery et al. shows that global longitudinal strain analysis can detect moderate and severe coronary artery disease comparable to the visual analysis during stress echo and reports that a global

longitudinal strain $< -20\%$ has a negative predictive value of 80% for lesions $>50\%$ and of 90% for lesions $>70\%$.

However, their results should be interpreted with care since 16% of patients had been previously revascularized, in a non-specified number of patients double focus capture was performed and patients with basal inferior and inferolateral hypokinesia were not excluded. (6) Moreover, many patients in our daily practice have -20% global strain and are young athletes or patients with mild left ventricular hypertrophy, so the implementation of this cut-off point can hardly avoid overlapping with patients free from coronary artery disease or even healthy subjects.

Choi et al. concluded that global 2D longitudinal strain was lower in 108 patients with 3-vessel or LMCA disease even without presenting abnormal contractility, with a cut-off point of -17.9% , and 79% sensitivity and specificity compared with normal patients. They confirmed that no patient with 3-vessel disease had normal 2D longitudinal strain, markedly differing from our results. It should be pointed out that in their work decreased values were only detected in medial and basal segments, as the authors claimed that the apex, due to its additional rotational movement, does not allow an adequate estimation of longitudinal function. However, we were able to perfectly appreciate these abnormal segments during acute ischemia analyzed at peak stress. (15)

In the study of Gaibazzi et al. with dipyridamole and simultaneous coronary reserve measurement, they could differentiate normal patients from patients with CA and significant lesions using longitudinal strain at rest. Nevertheless, we observed superposition of longitudinal strain values between normal patients and those with 1-vessel or 2-vessel coronary artery disease, so that its discrimination in the individual patient may be wrong. (7)

It is interesting to point out that in the publication of the Italian group no differences in longitudinal strain were found between patients with angina 24 hours prior to the study and asymptomatic patients. (7)

Other laboratories might also have similar results to the ones reported in this work and it is well known that negative studies are usually not published.

We believe that if longitudinal strain does not have memory of transient ischemic insults produced by stress echo, as shown in another article published in this issue of the Journal, (16) it is logical that transient spontaneous ischemia in coronary artery disease patients with no wall motion abnormalities should not present significant differences from normal patients in their regional and global longitudinal deformation.

Limitations

Although the population was not numerous, it was representative of patients studied in most laboratories. Not all patients had CA, but those with positive tests and CA (Group A) did not have different characteristics from those presenting with positive test

without CA (Group B). Given the high specificity of the test, it is difficult to assume that with the same baseline characteristics and evident positive results they did not have coronary artery disease.

Radial or circumferential deformation was not evaluated as there is lower intra- and inter- observer concordance, strain rate was not measured due to the low temporal resolution of speckle tracking and neither was postsystolic deformation assessed in this study.

Practical applications

Baseline longitudinal strain analysis should be routinely performed in all patients who are going to be evaluated with stress echo to compare with peak stress; however, a normal study does not provide additional information on the subsequent test outcome.

CONCLUSIONS

Baseline 2D longitudinal strain could not predict the test outcome or the presence of significant coronary artery disease in the absence of contractile abnormalities at rest.

Conflicts of interest

Jorge Lowenstein has received medical fees for conferences on behalf of the General Electric company. The rest of the authors do not have conflicts of interest.

(See authors' conflicts of interest forms in the web/Supplementary material)

REFERENCES

- Pellikka PA, Nagueh SF, Elhendy AA, Kuehl CA, Sawada SG. American Society of Echocardiography Recommendations for Performance, Interpretation, and Application of Stress Echocardiography. *J Am Soc Echocardiogr* 2007;20:1021-41. <http://doi.org/bn7jkh>
- Picano E. Echocardiographic Signs of Ischemia. En: Picano E. *Stress Echocardiography*. 5th ed. Springer; 2009. p. 75-89. <http://doi.org/cbh658>
- Moonen M, Lancellotti P, Zacharakis D, Pierard L. The value of 2D strain imaging during stress testing. *Echocardiography* 2009;26:307-14. <http://doi.org/cb5wd6>
- Lax J, Bermann A. Enfermedad coronaria. En: Cianciulli T, Prezioso H, Lax J. *Nuevas técnicas en ecocardiografía*. 1.a ed. Buenos Aires: Ediciones Journal; 2012. p. 161.
- Choi JO, Cho SW, Song YB, Cho SJ, Song BG, Lee SC, et al. Longitudinal 2D strain at rest predicts the presence of left main and three vessel coronary artery disease in patients without regional wall motion abnormality. *Eur J Echocardiogr* 2009;10:695-701. <http://doi.org/fgxdt3>
- Montgomery DE, Puthumana JJ, Fox JM, Ogunyankin KO. Global longitudinal strain aids the detection of non-obstructive coronary artery disease in the resting echocardiogram. *Eur Heart J Cardiovasc Imaging* 2012;13:579-87. <http://doi.org/bvmtmd>
- Gaibazzi N, Pigazzani F, Reverberi C, Porter TR. Rest global longitudinal 2D strain to detect coronary artery disease in patients undergoing stress echocardiography: a comparison with wall-motion and coronary flow reserve responses. *Echo Res Pract* 2014;1:61-70. <http://doi.org/bkf7>
- Picano E. *Echocardiographic. Stress Echocardiography*. 6th ed. Springer; 2015. p. 179-30. <http://doi.org/bkf8>
- Sicari R, Nihoyannopoulos P, Evangelista A, Kasprzak J, Lancellotti P, Poldermans D, et al. Stress echocardiography expert consensus statement: European Association of Echocardiography (EAE) (a registered branch of the ESC). *Eur J Echocardiogr* 2008;9:415-37. <http://doi.org/dvxxvq8>

10. Hoffmann R, Lethen H, Marwick T, Arnese M, Fioretti P, Pingitore A, et al. Analysis of interinstitutional observer agreement in interpretation of dobutamine stress echocardiograms. *J Am Coll Cardiol* 1996;27:330-6. <http://doi.org/bctq6m>
11. Marwick TH, Leano RL, Brown J, Sun JP, Hoffmann R, Lysyansky P, et al. Myocardial strain measurement with 2-dimensional speckle-tracking echocardiography: definition of normal range. *JACC Cardiovasc Imaging* 2009;2:80-4. <http://doi.org/dbxbnx>
12. Nakatani S. Left ventricular rotation and twist: why should we learn? *J Cardiovasc Ultrasound* 2011;19:1-6. <http://doi.org/bkt8tc>
13. Perk G, Kronzon I. Non-Doppler two dimensional strain imaging for evaluation of coronary artery disease. *Echocardiography* 2009;26:299-306. <http://doi.org/cxgh9z>
14. Götte MJ, Germans T, Rüssel IK, Zwanenburg JJ, Marcus JT, van Rossum AC, et al. Myocardial strain and torsion quantified by cardiovascular magnetic resonance tissue tagging: studies in normal and impaired left ventricular function. *J Am Coll Cardiol* 2006;48:2002-11. <http://doi.org/czr23q>
15. Caniggia C, Amor M, Lowenstein Haber D, Alasia D, Galello M, Darú V, et al. Feasibility and Contribution of Global and Regional 2D Strain during Exercise Stress. *Rev Argent Cardiol* 2014;82:110-1.
16. Lowenstein J, Gastaldello N, Merlo P, Galello M, Rousse M, Darú V. Longitudinal Strain has no Ischemic Memory. *Rev Argent Cardiol* 2016;84:351-354