

Strain by Nuclear Magnetic Resonance in Hypertrophic Cardiomyopathy

Strain por resonancia magnética nuclear en la miocardiopatía hipertrófica

ESTEBAN LUDUEÑA CLOS[†], BETTIANA TORTEROLO LOZANO, MARIANO SOTES, SILVIA MAKHOUL, ADRIANA GARCÍA, OSVALDO MANUALE

ABSTRACT

Background: New techniques have been developed for the quantitative analysis of myocardial deformation by cardiovascular magnetic resonance from cine-sequences (as feature tracking) or from sequences with myocardial saturation bands (tagging), enabling a reliable evaluation of the true systolic function in patients with hypertrophic cardiomyopathy.

Objectives: The aim of this study was to assess systolic function expressed as evaluation of ejection fraction and myocardial deformation by new analysis techniques in a population with hypertrophic cardiomyopathy.

Methods: Forty patients with hypertrophic cardiomyopathy were retrospectively included in the study between April 2009 and April 2016. Wall thickness values were estimated and endocardial and epicardial borders were traced for calculation of ventricular volumes and mass. Four-chamber and short-axis cine and tagging sequences defined the borders to analyze deformation or myocardial strain by feature tracking and myocardial tagging; values of global longitudinal, circumferential and radial strain were obtained and segmental strain curves were established.

Results: Mean ejection fraction in the overall population was $72\% \pm 9\%$. In the analysis of myocardial deformation by feature-tracking from 4-chamber and short-axis cine sequences, mean global longitudinal strain was $-9.9\% \pm 3\%$, circumferential strain $-14\% \pm 5\%$ and radial strain $33\% \pm 10\%$. In the values obtained by myocardial tagging, mean global longitudinal and circumferential strains were $-7\% \pm 3\%$ and $-17\% \pm 3\%$, respectively.

Conclusions: A global preserved ejection fraction was estimated in this population with hypertrophic cardiomyopathy, despite having a significant decrease in longitudinal, circumferential and radial myocardial deformation. That is why the new analysis techniques by cardiac MRI allow a deeper understanding of the real systolic function of patients suffering from this disease.

Key words: Cardiomyopathy, Hypertrophic - Magnetic Resonance Imaging - Myocardium/abnormalities

RESUMEN

Introducción: Se han desarrollado nuevas técnicas para el análisis cuantitativo de la deformación miocárdica por resonancia magnética cardíaca a partir de las secuencias de cine (como el *feature tracking*) o de secuencias con bandas de saturación miocárdica (*tagging*), que permiten una evaluación confiable de la verdadera función sistólica ventricular en pacientes con miocardiopatía hipertrófica.

Objetivo: Analizar la función sistólica expresada en la evaluación de la fracción de eyección y de la deformación miocárdica por las nuevas técnicas de análisis en una población con miocardiopatía hipertrófica.

Material y métodos: Entre abril de 2009 y abril de 2016 se incluyeron en forma retrospectiva 40 pacientes portadores de miocardiopatía hipertrófica. Se estimaron los espesores parietales y se trazaron los bordes endocárdicos y epicárdicos para el cálculo de volúmenes y masa ventriculares. En los cines y secuencias de *tagging* en 4 cámaras y eje corto se definieron los bordes para el análisis de deformación o *strain* miocárdico por *feature tracking* y *tagging* miocárdico; se obtuvieron valores de *strain* global longitudinal, circumferencial y radial y se establecieron curvas de *strain* segmentario.

Resultados: La media de fracción de eyección de la población total fue del $72\% \pm 9\%$. En el análisis de deformación miocárdica por *feature tracking* de los cines de 4 cámaras y eje corto, la media del *strain* longitudinal global fue de $-9,9\% \pm 3\%$, la del *strain* global circumferencial fue de $-14\% \pm 5\%$ y la del radial fue de $33\% \pm 10\%$. En los valores obtenidos por *tagging* miocárdico, la media del *strain* longitudinal global fue de $-7\% \pm 3\%$ y la del circumferencial global fue de $-17\% \pm 3\%$.

Conclusiones: Se estimó una fracción de eyección global conservada en esta población portadora de miocardiopatía hipertrófica, a pesar de presentar una disminución significativa en la deformación miocárdica longitudinal, circumferencial y radial. Es por ello que las nuevas técnicas de análisis por resonancia magnética cardíaca permiten conocer más profundamente la función sistólica real de los portadores de esta enfermedad.

Palabras clave: Miocardiopatía hipertrófica - Imagen por resonancia magnética - Miocardio/anormalidades

REV ARGENT CARDIOL 2016;84:342-346. <http://dx.doi.org/10.7775/rac.v84.i4.8966>

SEE RELATED ARTICLE: REV ARGENT CARDIOL 2016;84:300-301. <http://dx.doi.org/10.7775/rac.v84.i4.9175>

Received: 05/13/2016 – Accepted: 06/27/2016

Address for reprints: Esteban Ludueña Clos - Servicio de Cardiología, Hospital Británico de Buenos Aires - Perdriel 74 - CABA - e-mail:estebanclos@hotmail.com

Abbreviations

CMR	Cardiac magnetic resonance	MTAG	Myocardial tagging
HCM	Hypertrophic cardiomyopathy	CMR-FT	Cardiac magnetic resonance feature tracking

INTRODUCTION

The development of new techniques to assess myocardial deformation has broadened the scope for the analysis of various myocardial diseases. Myocardial saturation bands (tagging) in the field of cardiovascular magnetic resonance (CMR) and analysis by tissue Doppler or two-dimensional speckle tracking echocardiography are among the pioneering techniques used in this area. Cardiovascular magnetic resonance has a wide field of view and excellent definition of myocardial borders with respect to the blood pool, allowing high quality images for anatomical and functional studies, as well as volume estimation to calculate left and right ventricular ejection fraction. It is well known that left ventricular ejection fraction may not be sensitive enough to detect subtle changes in left ventricular systolic function, especially in the early stages of a cardiomyopathy. (1)

Up to the present, it has been difficult in CMR to quantitatively estimate the degree of myocardial deformation, which is conditioned to only visual estimation through myocardial tagging sequences (loss of segmental grid perpendicularity). However, the development of new analysis computer programs has improved myocardial deformation analysis from a mere qualitative evaluation to a detailed quantitative global and segmental study.

Among the recently developed CMR techniques to assess myocardial deformation, feature tracking (FT-CMR) analysis allows the quantification of wall motion and deformation by tracing ventricular endocardial and epicardial borders from classical cine sequences (steady state free precession, SSFP). This type of study has been validated by myocardial tagging sequences using harmonic phase analysis (HARM) and spatial modulation displacement (SPAMM). (2, 3) One of its main virtues is the short time required to perform it and its application in the myocardial cine sequences of a conventional CMR study.

It is possible to estimate longitudinal, circumferential or radial myocardial deformation, and similar normal values have been reported both for echocardiography as CMR.

Global left ventricular deformation values reported by two-dimensional speckle tracking echocardiography in healthy subjects are: longitudinal: $-21.5\% \pm 2.0\%$, circumferential: $-22\% \pm 3.4\%$ and radial: $40.1\% \pm 11.8\%$. (4). In the case of FT-MRC, deformation values are: longitudinal: $-21.3\% \pm 4.8\%$, circumferential: $-26.1\% \pm 3.8\%$ and radial: $39.8\% \pm 8.3\%$. (5)

The presence of dysfunctional sarcomeric proteins, myocyte hypertrophy, fibril disarray and development of interstitial fibrosis interfere with systolic cardi-

al mechanics, despite hyperdynamic systolic function; (6) hence, the great usefulness of these techniques of myocardial deformation analysis to unmask and reliably evaluate the true ventricular systolic function. The importance of the information provided by this analysis has been emphasized in the different stages of the disease, especially in the pre-clinical phase, for an accurate diagnostic and therapeutic conduct.

METHODS

Patients with diagnosis of hypertrophic cardiomyopathy (HCM) who had been referred to the CMR laboratory to complete the diagnosis, evaluate the extent of hypertrophy, rule out other etiological causes of myocardial thickening, estimate the ejection fraction (and systolic function) and assess the presence of fibrosis through delayed gadolinium enhancement were retrospectively included between April 2009 and April 2016.

Studies were performed with two Philips Achieva 1.5 Tesla systems from the hospital and all images were acquired by means of a body surface antenna during repeated breath-holds and using electrocardiographic synchronization and monitoring with a respiratory navigator.

Axial anatomic images were initially acquired in black blood to then plan 2-chamber, short-axis, 4-chamber and left ventricular outflow tract cine sequences for the functional study (flip angle: 60° , section thickness: 8 mm, 30 frames per cardiac cycle). Radial apex to base sections were subsequently performed to calculate end-diastolic, end-systolic and stroke volumes, ejection fraction and myocardial mass (by automatic segmentation). Myocardial tagging sequences were performed, consisting in the application of myocardial segment saturation bands (grid) maintained for a space of time during the acquisition, as the signal decays during the course of the cardiac cycle, but acts as a label, allowing the visualization of myocardial deformation during ventricular contraction and relaxation. Finally, non-ferromagnetic contrast material was administered (gadolinium) for delayed myocardial enhancement sequences in the same cine imaging planes. The analysis of all images was performed with the free Segment version v2.0 R5024 software. (7-9) Wall thicknesses were estimated and endocardial and epicardial borders were traced to calculate ventricular volumes and mass. The borders for the analysis of myocardial deformation or strain by FT-CMR (Figure 1) and MTAG (10, 11) were defined from 4-chamber and short axis cine and tagging sequences (Figure 2); global longitudinal, circumferential and radial strain values were obtained and segmental strain curves were established (Figure 3).

Statistical analysis

Epi Info version 7.1.5-2 software was used to calculate the mean and standard deviation of continuous variables and frequencies.

Ethical considerations

Patients signed an informed consent and the data were anonymously incorporated into the database.

Fig. 1. Feature tracking in 4-chamber and short-axis cine images (see color image in the web).

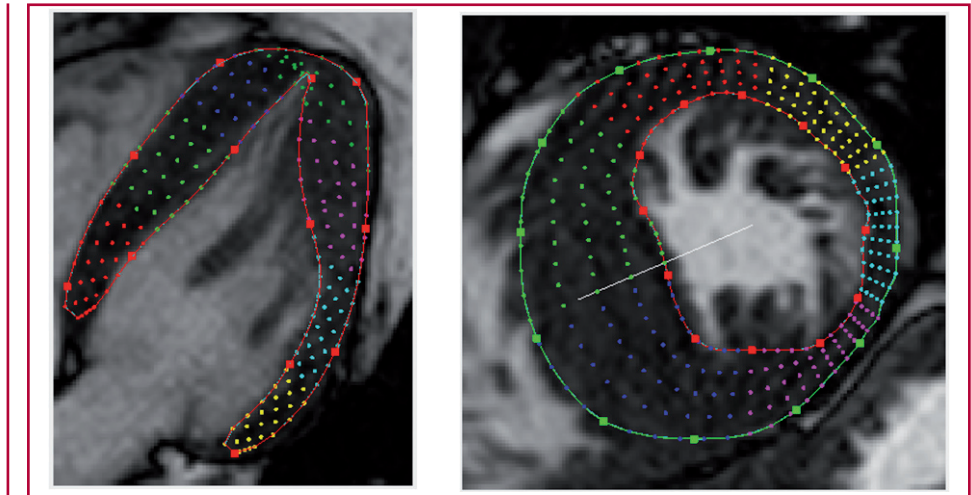


Fig. 2. Four-chamber and short-axis myocardial tagging (see color image in the web).


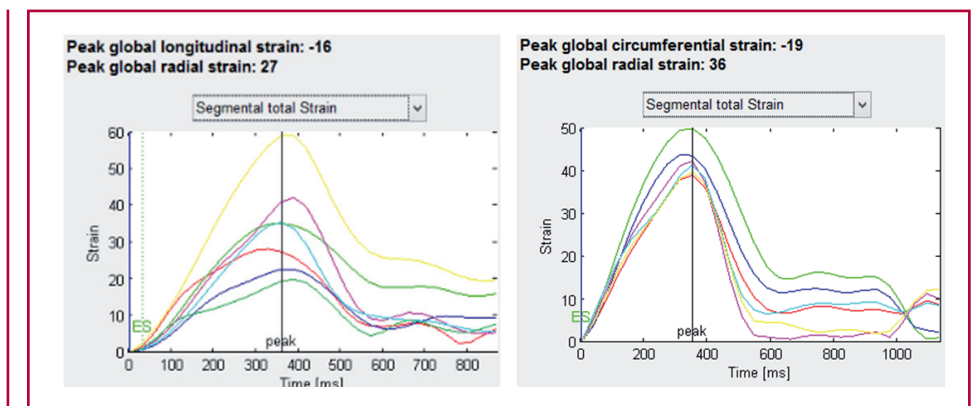


Fig. 3. Segmental longitudinal and circumferential strain curves.



RESULTS

A total of 40 patients with diagnosis of HCM (Table 1), 71% of whom were men, were included in the study. Mean age was 52 ± 17 years. Clinically, 68% of patients were in FC I and 32% in FC II. In the electrocardiographic study, 85% of patients evidenced sinus rhythm and the remaining 15%, atrial fibrillation. Sixty-two percent of patients had a positive Sokolow-Lyon index and 20% presented non-sustained and 8% sustained ventricular tachycardia. The distribution of hypertro-

phy was asymmetric in 67% of patients, apical in 21% and concentric in 12% of cases, with dynamic left ventricular outflow tract obstruction in 34% of patients. Mean ventricular mass was 213 ± 60 grams and mean highest wall thickness was 21 ± 7 mm. Delayed gadolinium enhancement was observed in 64% of patients (see Table 1).

Mean ejection fraction of the total population was $72\% \pm 9\%$. In the FT-CMR myocardial deformation analysis from 4-chamber and short-axis cine im-

Table 1. Characteristics of the population with hypertrophic cardiomyopathy (n=40)

Age, years	52±17
Sex (Male/Female), %	71/29
Rhythm (sinus/atrial fibrillation), %	85/15
NYHA functional class (I/II/III/IV), %	68/32/0/0
NSVT/VT, %	20/8
LV mass, g (mean±SD)	213±60
LVOT obstruction, %	34
Delayed gadolinium enhancement, %	64

NYHA: New York Heart Association. NSVT: Non-sustained ventricular tachycardia. VT: Ventricular tachycardia. LV: Left ventricular. SD: Standard deviation. LVOT: Left ventricular outflow tract.

ages, mean global longitudinal strain was $-9.9\% \pm 3\%$, global circumferential strain $-14\% \pm 5\%$ and radial strain $33\% \pm 10\%$. Mean global longitudinal strain by MTAG was $-7\% \pm 3\%$ and global circumferential strain $-17\% \pm 3\%$ (Table 2).

DISCUSSION

The difficult availability of systems to acquire and subsequently analyse myocardial deformation leads in many cases to restrict left or right ventricular systolic function estimation to ejection fraction in patients with HCM. As reported in the national and foreign literature, it is well known that ejection fraction may be normal or even increased (12) despite presenting a marked reduction of myocardial deformation. (13, 14) However, both qualitatively in myocardial tagging sequences (where a drastic reduction or absence of loss of grid perpendicularity in myocardial hypertrophic segments is observed) as quantitatively in the deformation analysis by new analysis techniques, there is evidence of the deficit in capacity and effective contractile mass.

In our work, the population presented preserved global ejection fraction values. However, strain analyzed either by FT-HCM or MTAG was significantly decreased.

Thus, CMR is able to complement the echocardiographic evaluation or be an alternative for patients with suboptimal ultrasound image.

The analysis of larger populations with this disease will allow comparing different groups according to age, sex, presence of fibrosis, etc, and assess systolic function in preclinical stages of the disease. As limitation, cine images obtained by magnetic resonance imaging are not always of optimal quality, in some cases due to the presence of arrhythmia or the difficulty of patients to perform breath-holds, though fortunately this occurs in a low percentage of studies. FT-CMR and MTAG can be extended to other planes of cine imaging analysis, as for example 2-chamber, left ventricular outflow tract, etc, to incorporate them in future lines of work.

Table 2. Strain by feature tracking and myocardial tagging

Feature tracking	
Global longitudinal strain, %	-10±3
Global circumferential strain, %	-14±5
Global radial strain, %	33±10
Myocardial Tagging	
Global longitudinal strain, %	-7±3
Global circumferential strain, %	-17±3

CONCLUSIONS

Cardiovascular magnetic resonance is an important tool for the study of patients with hypertrophic cardiomyopathy. New analysis techniques of myocardial deformation or strain used in this work allowed exposing left ventricular systolic function impairment, despite a preserved ejection fraction.

Conflicts of interest

None declared. (See authors' conflicts of interest forms in the website/Supplementary material).

REFERENCES

- Nagueh SF, Bachinski LL, Meyer D, Hill R, Zoghbi WA, Tam JW, et al. Tissue Doppler imaging consistently detects myocardial abnormalities in patients with hypertrophic cardiomyopathy and provides a novel means for an early diagnosis before and independently of hypertrophy. *Circulation* 2001;104:128-30. <http://doi.org/qx6>
- Hor KN, Gottliebson WM, Carson C, Was E, Cnota J, Fleck R, et al. Comparison of magnetic resonance feature tracking for strain calculation with harmonic phase imaging analysis. *JACC Cardiovasc Imaging* 2010;3:144-51. <http://doi.org/b59h4d>
- Moody WE, Taylor RJ, Edwards NC, Chue CD, Umar F, Taylor TJ, et al. Comparison of magnetic resonance feature tracking for systolic and diastolic strain and strain rate calculation with spatial modulation of magnetization imaging analysis. *J Magn Reson Imaging* 2015;41:1000-12. <http://doi.org/bkdd>
- Kocabay G, Muraru D, Peluso D, Cuchini U, Mihaila S, Padayattil-Jose S et al. Normal left ventricular mechanics by two-dimensional speckle-tracking echocardiography. Reference values in healthy adults. *Rev Esp Cardiol* 2014;67:651-8. <http://doi.org/f2rd8v>
- Taylor RJ, Moody WE, Umar F, Edwards NC, Taylor TJ, Stegemann B, et al. Myocardial strain measurement with feature-tracking cardiovascular magnetic resonance: normal values. *Eur Heart J Cardiovasc Imaging* 2015;16:871-81. <http://doi.org/bkdf>
- Carasso S, Yang H, Woo A, Vannan MA, Jamorski M, Wigle ED, Rakowski H. Systolic myocardial mechanics in hypertrophic cardiomyopathy: novel concepts and implications for clinical status. *J Am Soc Echocardiogr* 2008;21:675-83. <http://doi.org/bg6m3h>
- Heiberg E, Sjögren J, Ugander M, Carlsson M, Engblom H, Arheden H. Design and validation of Segment- freely available software for cardiovascular image analysis. *BMC Med Imaging* 2010;10:1. <http://doi.org/fwm5wr>
- Tufvesson J, Hedström E, Steding-Ehrenborg K, Carlsson M, Arheden H, Heiberg E. Validation and development of a new automatic algorithm for time-resolved segmentation of the left ventricle in magnetic resonance imaging. *Biomed Res Int* 2015;2015:970357.
- Heiberg E, Wigström L, Carlsson M, Bolger AF, Carlsson M. Time Resolved Three-dimensional Segmentation of the Left Ventricle. *Proceedings of IEEE Computers In Cardiology* 2005;32:599-602.
- Heyde B, Jasaityte R, Barbosa D, Robesyn V, Bouchez S, Wouters P, et al. Elastic image registration versus speckle tracking for 2-D myocardial motion estimation: a direct comparison in vivo. *IEEE*

Trans Med Imaging 2013;32:449-59. <http://doi.org/bkdg>

11. Morais P, Heyde B, Barbosa D, Queirós S, Claus P, D'hooge J. Cardiac motion and deformation estimation from tagged MRI sequences using a temporal coherent image registration framework. Proceedings of the meeting on Functional Imaging and Modelling of the Heart (FIMH). Lecture Notes in Computer Science 2013;7945:316-2. <http://doi.org/bkdh>

12. Wigle ED, Rakowski H, Kimball B, Williams W. Hypertrophic cardiomyopathy. Clinical spectrum and treatment. Circulation

1995;92:1680-92. <http://doi.org/bkdj>

13. Serri K, Reant P, Lafitte M, Berhouet M, Le Bouffos V, Roudaut R, et al. Global and regional myocardial function quantification by two-dimensional strain: application in hypertrophic cardiomyopathy. J Am Coll Cardiol 2006;47:1175-81. <http://doi.org/cpsrzm>

14. Baratta S, Chejtman D, Fernández H, Ferroni FE, Bilbao J, Kotliar C y cols. Valor clínico de la utilización del strain rate sistólico en el estudio de distintas formas de hipertrofia ventricular izquierda. Rev Argent Cardiol 2007;75:367-73.