

3. Preliminary report: effect of encainide and flecainide on mortality in a randomized trial of arrhythmia suppression after myocardial infarction. The Cardiac Arrhythmia Suppression Trial (CAST) Investigators. *N Engl J Med* 1989;321:406-12. <http://doi.org/czpkfc>
4. Azocar D, Dubner SJ, Labadet CD, Hadid C, Valsecchi MC, Domínguez AE y cols. Ablación por radiofrecuencia de arritmia ventricular frecuente guiada por catéter multielectrodo Array. *Rev Argent Cardiol* 2014;82:416-20. <http://doi.org/42r>
5. Moss AJ, Greenberg H, Case RB, Zareba W, Hall WJ, Brown MW, et al; Multicenter Automatic Defibrillator Implantation Trial-II (MADIT-II) Research Group. Long-term clinical course of patients after termination of ventricular tachyarrhythmia by an implanted defibrillator. *Circulation* 2004;110:3760-5. <http://doi.org/cpvfv4>
6. Miyamoto K, Tsuchiya T, Yasuoka C, Tanioka Y. A case of radiofrequency catheter ablation of ventricular tachycardia associated with an old myocardial infarction guided by a noncontact mapping system. *J Arrhythmia* 2009;25:36-41. <http://doi.org/42s>

Rev Argent Cardiol 2015;83:355-357. <http://dx.doi.org/10.7775/rac.v83.i4.5644>

Cardiac tamponade in disseminated cryptococcosis

Cryptococcosis is an opportunistic fungal disease caused by an encapsulated yeast, *Cryptococcus neoformans* (CN). The perfect state of the basidiomycetes is *Filobasidiella neoformans*, which has two varieties: *neoformans* and *bacillispora*. Five serotypes and two different varieties have been identified: CN var. *neoformans* (A, B and AD) and CN var. *gattii* (B and C). (1)

Cryptococcosis is an important cause of infection in patients with human immunodeficiency virus; it has no sex predilection though it is more common in men between 30 and 60 years, and, to a less extent, in children.

Exposure to pigeon feces or air-conditioning systems contaminated with bird droppings is a risk factor. Several infectious agents produce infective pericardial effusion; CN is one of them, with mortality between 15% and 30%. (2, 3)

We present a case report of cardiac tamponade in disseminated cryptococcosis (DC).

A 46-year-old male patient was admitted to the intensive care unit due to rapidly progressive dyspnea and consciousness deterioration. He had a history of dilated cardiomyopathy due to acquired immunodeficiency syndrome (AIDS) under antiretroviral therapy. He had had a previous hospitalization a short time ago with DC diagnosis, meningeal and lung involvement, severe hypoacusia and kidney dysfunction. At admission, the patient was confused and did not present fever (36.2 °C); his blood pressure was 70/40 mm Hg, he had jugular engorgement, poor distal perfusion and tachypnea (25 breaths per minute). Crackles were heard over both lung bases and a grade 1/6 systolic murmur was heard over the tricuspid area.

The electrocardiogram indicated sinus rhythm with a heart rate of 110 beats per minute and low QRS voltage in the frontal and precordial leads. The chest X-ray showed cardiac enlargement and diffuse redistribution of blood flow in both pulmonary fields. In

the laboratory tests, erythrocyte sedimentation rate was elevated (58 mm), the hematocrit was 30%, BUN 120 mg/dl, creatinine levels 2.2 mg/dl, and creatinine clearance 38.57 ml/min.

Doppler echocardiography showed mild left ventricular dilatation, normal wall thickness, global hypokinesia and severe left ventricular dysfunction with an ejection fraction of 24%. The left atrium was moderately dilated, with an estimated area of 29 cm². The dimensions of the right chambers were normal and the right ventricle had mild ventricular dysfunction. Opening of the trileaflet aortic valve was normal. The mitral valve had mild regurgitation and restrictive left ventricular filling pattern. The presence of mild tricuspid regurgitation allowed the estimation of systolic pulmonary artery pressure of 50 mm Hg. A severe circumferential pericardial effusion was observed and the pericardial layers were separated by 19 mm (posterior effusion), 17 mm (lateral effusion) and 6 mm (anterior effusion). Echocardiographic signs of cardiac tamponade were present, with early diastolic collapse of the right ventricular anterior wall and diastolic collapse of the right atrium, dilated inferior vena cava of 32 mm with inspiratory collapse <50% (Figures 1 and 2).

The patient required endotracheal intubation, mechanical ventilation and hemodynamic support with vasoactive drugs. He underwent emergency pericardiocentesis, and after 400 ml of blood stained fluid were drained, the hemodynamic parameters experienced immediate recovery.

Further examination of pericardial fluid was positive for CN antigen, and quantitative analysis was performed by latex test.

Microscopic examination with India ink stain and pericardial fluid culture were positive for CN.

The infectologists indicated fluconazole 200 mg for life because of the unfavorable outcome and disseminated form; the patient is currently taking this medication.

The incidence of cryptococcosis in AIDS patients varies among the different regions of the world, from 50-10% in Western Europe and in the United States, to 20% or more in Central Africa and Southeast Asia. In Argentina, the incidence would be 4.6% according to official public health agencies. (4) Infection is acquired by inhalation of air-borne yeast cells present in nature that easily reach the pulmonary alveoli. Neither person-to-person nor animal-to-human respiratory transmission has not been documented, but transmission via organ transplantation has been reported. Physicians should suspect this disease to make the diagnosis. (1)

Pericardial involvement occurs as pericarditis, asymptomatic pericardial effusion or cardiac tamponade. The prevalence of pericardial involvement ranges between 3% and 37%. (5)

The typical signs and symptoms of heart failure (HF) may be difficult to recognize in a population of

patients in whom the systemic symptoms of HF overlap with those of cryptococcosis and in whom the incidence of pulmonary disease is higher than that of heart disease. The clinical manifestations of HF appear during the late stages of the disease. Astenia and discomfort as symptoms of low cardiac output may be easily attributed to AIDS. Jugular engorgement and edemas are usually absent. Only a minority of patients with asymptomatic ventricular dysfunction have sinus tachycardia at rest as single manifestation. (6) In cardiac tamponade, the clinical signs of hemodynamic impairment may be absent in patients with cachexia and low right ventricular filling pressures. (3)

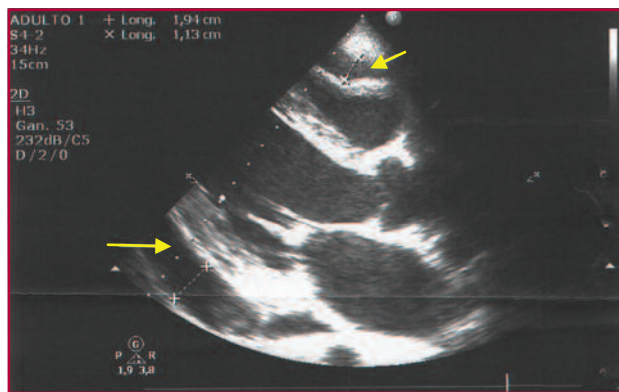


Fig. 1. Transthoracic echocardiography. Parasternal long-axis view. A severe circumferential pericardial effusion is observed, 16 mm posteriorly and 6 mm anteriorly, with early diastolic collapse of the right ventricular anterior wall

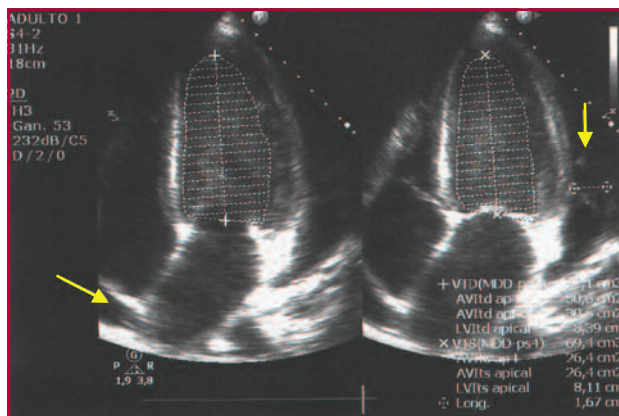


Fig. 2. Transthoracic echocardiography. Four-chamber apical view. Pericardial effusion is observed, 17 mm laterally, with diastolic collapse of the right atrium.

The diagnosis of cryptococcosis is based on direct observation of the etiological agent with India ink staining. Cultures should be prepared in Sabouraud medium or in other media not containing cycloheximide, and have optimal growth between 32 °C and 37 °C. Growth is inhibited at 40 °C. The histopathological findings are described as jelly-like areas with abundant cryptococci and minimal inflammation or granulomatous infiltrates, with minimal cryptococci and marked inflammatory reaction with lymphocytes, monocytes and giant cells. The presence of antigens or antibodies in serum or cerebrospinal fluid is positive in 77% to 99% of cases. A positive test indicates disseminated disease and high titers correlate with the severity of the disease and with the response to treatment.

Treatment depends on two factors: the anatomic site involved and host immune status. Azole derivatives are prescribed for 2 to 6 months in immunocompetent patients, but in patients with AIDS treatment is for life. (2)

Disseminated cryptococcosis is an uncommon disease and should be highly suspected to reach a diagnosis, as its association with AIDS increases mortality, particularly when associated with pulmonary artery hypertension and cardiac tamponade.

Ulises Godoy¹, Leandro Rodríguez Pardo¹, Juan Medrano¹, Miguel Curone²

¹ Department of Cardiology and ² Intensive Care Unit
Clínica y Maternidad Suizo Argentina. Buenos Aires, Argentina
Av. Pueyrredón 1461 - (1118) Buenos Aires, Argentina
Phone number: 011 5239-6071 - e-mail: ulisesgodoy31@gmail.com

REFERENCES

1. De Kok E, Cirocco A, Ruiz A. Criptococosis diseminada: a propósito de un caso. *Dermatología Venezolana* 2004;42:22-4.
2. Arenas R. *Criptococosis. Micología médica ilustrada*. 3.a ed. México: McGraw-Hill Interamericana; 2008. p. 239-46.
3. Schuster M, Valentine F, Holtzman R. Cryptococcal pericarditis in an intravenous drug abuser. *J Infect Dis* 1985;152:842. <http://doi.org/bk79zc>
4. Negroni R. Las micosis en el SIDA. *Rev Arg Micol* 1990;13:3-14.
5. Welch K, Finkbeiner W, Alpers CE, Blumenfeld W, Davis RL, Smuckler EA, et al. Autopsy findings in the acquired immune deficiency syndrome. *JAMA* 1984;252:1152-9. <http://doi.org/ch6pgb>
6. Herskowitz A, Baughman K. Efecto de la infección por el HIV sobre el corazón. En: Braunwald E, editor. *Heart disease update*. Baltimore: WB Saunders Company 1996;1-11.