

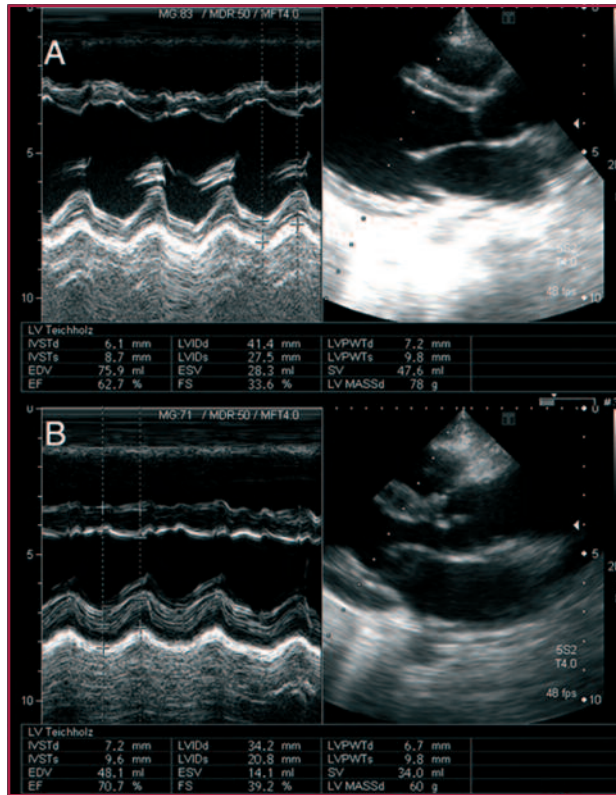Fig. 2. Transthoracic echocardiographic measurements. **A.** Pre-operative. **B.** One-year postoperative control

a low rate of endocarditis, limiting surgery to the diseased valve and allowing growth of the ventricular outflow tract together with the somatic growth of the patient.

We had already described the concept of “bicuspidization” of unicuspid valves, creating a new commissure with normal height and adding pericardial tissue to replace the lack of native valve tissue (3). We have recently proposed a technical modification that acquires a more symmetrical bicuspid design (6).

The case we report demonstrates that this concept also applies to regurgitant valves due to CAS treatment. The initial functional result is close to that of a normal valve. As with any novel approach mid-term results are still limited and no data on long-term durability is available. Even if it was limited to 5 or 10 years, this would allow the child time to grow before applying a more definitive solution. Furthermore, a new valve reconstruction could be performed if the somatic growth of the child caused the used pericardial patches to become “small”.

The reconstruction of the aortic valve should be the technique of choice if significant aortic regurgitation occurs after CAS surgical or interventional treatment.

**Carlos Porras¹, Hans-Joachim Schäfers¹,
Ignacio Zabala¹, Fernando Cabrera¹,
María Ángeles Izquierdo², Miguel Such¹**

¹Heart Unit. Hospital Xánit Internacional.

Benalmádena. Málaga, España

²Pediatric Cardiology. Hospital Materno-Infantil

Donostia, San Sebastián

e-mail: carlos.porras@institutocardiotecnologico.com

REFERENCES

1. Alsoufi B, Al-Halees Z, Manliot C, McCrindle BW, Al-Ahmedi M, Sallehuddin A, et al. Mechanical valves versus the Ross procedure for aortic valve replacement in children: propensity-adjusted comparison of long-term outcomes. *J Thorac Cardiovasc Surg* 2009;137:362-70. <http://doi.org/bjg5c9>
2. Mokhles MM, Rizopoulos D, Andrinopoulou ER, Bekkers JA, Roos-Hesselink JW, Lesaffre E, et al. Autograft and pulmonary allograft performance in the second post-operative decade after the Ross procedure: insights from the Rotterdam Prospective Cohort Study. *Eur Heart J* 2012;33:2213-24. <http://doi.org/rzj>
3. Schäfers HJ, Aicher D, Riodionycheva S, Lindinger A, Rädle-Hurst T, Langer F, et al. Bicuspidization of the unicuspid aortic valve: a new reconstructive approach. *Ann Thorac Surg* 2008;85:2012-8. <http://doi.org/bq4kq4>
4. Bierbach BO, Aicher D, Issa OA, Bomberg H, Gräber S, Glombitza P, et al. Aortic root and cusp configuration determine aortic valve function. *Eur J Cardiothorac Surg* 2010;38:400-6. <http://doi.org/cp29hp>
5. Anderson RH. Understanding the structure of the unicuspid and unicommissural aortic valve. *J Heart Valve Dis* 2003;12:670-3.
6. Aicher D, Bewarder M, Kindermann M, Abdul-Khalique H, Schäfers HJ. Aortic valve function after bicuspidization of the unicuspid aortic valve. *Ann Thorac Surg* 2013;95:1545-50.

REV ARGENT CARDIOL 2014;82:313-314 - <http://dx.doi.org/10.7775/rac.v82.i4.2891>

Aortopulmonary Window Associated with Tetralogy of Fallot

The aortopulmonary window (APW) is a rare congenital malformation which occurs in 1 out of each 100,000 live births, representing 0.15% of all congenital heart defects. It is defined as an abnormal communication between the aorta and the pulmonary artery and / or right pulmonary branch, above the two separate normally formed semilunar valves. (1) It may occur alone, but it is commonly associated with another congenital heart disease. It varies in size and location, resulting in different classifications, those of Robinson and Mori being the most commonly employed at present.

This communication produces a large left - right (L-R) shortcircuit similar to a large patent ductus arteriosus (PDA), leading to congestive heart failure and early development of pulmonary hypertension. Surgical treatment is indicated at diagnosis. The prognosis of untreated patients is poor with 40% mortality in the first year of life. (2)

We describe the case of a male patient, with a diabetic mother, born at term by cesarean section with a birth weight of 3090 g. At 9 days old he is referred to cardiology as a result of a heart murmur. Tetralogy of Fallot is diagnosed and he continues with cardiovascular ambulatory follow-up with atypical evolution, tachypnea, radiological cardiomegaly, dilated left heart chambers and echocardiographic pulmonary hy-

perflow signs, under oral furosemide treatment.

He is admitted to the clinic on September 5, 2011 at the age of 7 months with respiratory distress, subcostal and intercostal retractions, prolonged expiration, wheezing, tachypnea, tachycardia, systolic murmur in every foci, S3 at the apex and 92% oxygen saturation with ambient air. Two days later he is transferred to intensive care due to general malaise, fever, reticular rash, bilateral crackles, and hepatomegaly. Samples are taken for virological examination. Decompensated congestive heart failure by an infectious respiratory process is presumed. Oseltamivir, ceftriaxone, spironolactone, furosemide, digoxin, and enalapril treatment is started.

Echocardiography shows pink tetralogy of Fallot with mild pulmonary infundibular and valve stenosis with 36 mmHg gradient, pulmonary hyperflow, severe dilation of the left heart chambers, moderate right ventricular hypertrophy, persistence of the left superior vena cava (LSVC), dilated coronary sinus, right aortic arch, and adequate biventricular function.

Forty-eight hours later, the patient is admitted under assisted mechanical ventilation (AMV) due to clinical condition deterioration with positive virological test for respiratory syncytial virus together with pneumonia. After 15 days of antibiotic treatment, with the infectious process controlled, the patient remains on AMV; and because of diagnostic uncertainty due to dilation of the left chambers and pulmonary hyperflow data, cardiac catheterization is indicated.

On September 22, 2011, cardiac catheterization reports tetralogy of Fallot with mild infundibular and valve stenosis with a 40 mm Hg gradient, large type 1 APW, moderate pulmonary hypertension distal to the window, right aortic arch, normal coronary arteries, persistence of the LSVC with absent innominate vein, dilated coronary sinus, and severe dilation of the left heart chambers (Figure. 1).

On September 24, 2011, catheter-related sepsis is found, with culture positive for coagulase negative and methicillin resistant staphylococcus and *Candida albicans*. Treatment is initiated with vancomycin and fluconazole. After controlling the infection he undergoes corrective surgery on October 17, 2011, weighing 4150 g.

Median sternotomy is performed. A large pericardial patch is resected and treated with glutaraldehyde, and a large dilated left atrium and type 1 APW is found (Figure 2). The three caval veins, the aorta close to the proximal end of the innominate artery (distal to the APW) and the right superior pulmonary vein are cannulated. Immediately after the initiation of extracorporeal circulation (ECC) a tourniquet is applied to both pulmonary branches. The anterior aspect of the APW in its pulmonary end is incised under moderate hypothermia, aortic cross clamping, and antegrade cardioplegia, continuing up to the posterior aspect, totally separating the aorta from the pulmonary trunk. Priority is given to direct closure of the

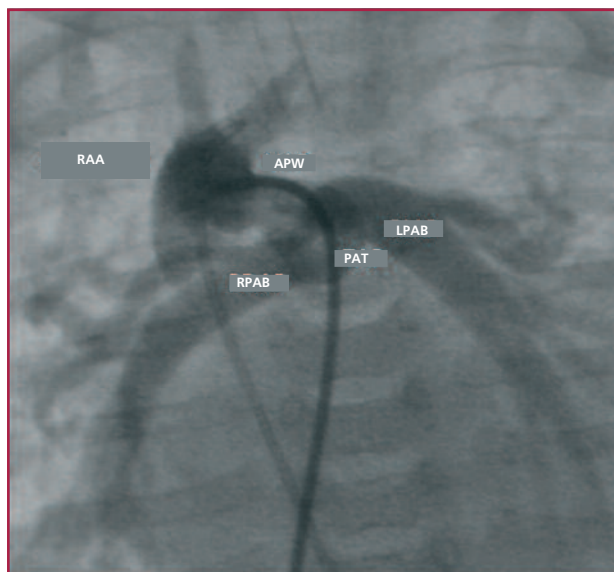


Fig. 1. Anteroposterior angiography from the right aortic arch, by venous catheter, shows aortopulmonary window, dilated pulmonary branches, and pulmonary artery trunk. The arterial catheter is in the right side and the venous catheter enters by the pulmonary artery trunk and passes to the right aortic arch through the aortopulmonary window.

RAA: Right aortic arch. APW: Aortopulmonary window. LPAB: Left pulmonary artery branch. RPAB: Right pulmonary artery branch. PAT: Pulmonary artery trunk.

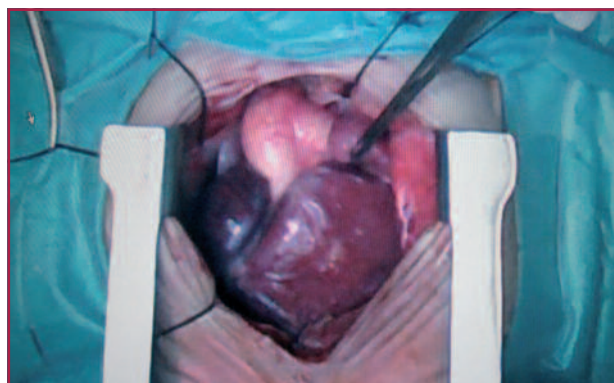


Fig. 2. Surgical photograph where median sternotomy, great cardiac chamber dilation and type 1 aortopulmonary window are observed.

aorta with 5-0 prolene. Pulmonary arteriotomy is extended to the proximal end, valve commissurotomy is accomplished and Hegar dilators are passed towards the ring and branches. Right atriotomy is performed, the infundibular stenosis is resected through the tricuspid valve and the interventricular communication (IVC) is closed with subaortic pericardial patch and 5-0 prolene continuous suture. The pulmonary artery is closed with a pericardial patch and prolene 6-0, followed by atriotomy closure, deaeration maneuvers and aortic unclamping. After weaning from ECC, modified hemofiltration is initiated extracting 220 cm³. ECC

time: 165 minutes and aortic cross-clamping time: 104 minutes. The patient leaves the operating room with open chest, and adrenaline and milrinone infusion. Forty-eight hours later, the chest is closed and 10 days after the patient is extubated. He is discharged from hospital at 21 days postoperatively.

After 22-months follow-up the patient is asymptomatic, with no cardiac medication, and a weight of 13 kg. The echocardiogram shows closed IVC without residual shunt, mild pulmonary valve stenosis without hemodynamic repercussions, with normal aortic flow and ventricular diameters.

The aortopulmonary window can occur alone, but in 10% of cases it is associated with other lesions (3, 5). The variation in terms of location and size gives rise to different classifications. The most commonly used are Richardson's classification that divides it into type 1, 2 and 3 and Mori's classification that divides it into proximal, distal and total.

Type 1 or proximal: the defect is located between the ascending aorta and the pulmonary trunk above the Valsalva sinuses. Type 2 or distal: the defect is more distal between the ascending aorta and the pulmonary trunk involving the origin of the right pulmonary artery. Type 3 or total: the right pulmonary artery arises from the ascending aorta.

Both the type of associated lesion as the APW size affects the patient's clinical condition. In infants with isolated APW, signs and symptoms of heart failure usually develop early and its presentation is similar to a large ductus or IVC. The continuous heart murmur is heard only in less than half of the cases (when the defect is small) and the ECG and chest X-ray are nonspecific, evidencing a large L-R short circuit with cardiomegaly and pulmonary hyperflow. Echocardiography should distinguish the presence of two separate semilunar valves, which allows differentiating the APW from the trunkus arteriosus. It is vital to define the distance between the proximal border of the defect and the valves, the position of the coronary arteries, and the distance between the distal border and the pulmonary branches. (6).

Surgical experience in APW is limited since it is a very rare defect. Mortality ranges from 8 to 30%, depending on the age at surgery, pulmonary vascular resistance, associated lesions and patient condition. (2, 4, 5, 7, 8) Once diagnosed, it should be corrected as early as possible

Simple ligation or division has relatively high frequency of complications, such as recanalization, bleeding and narrowing of the aorta or pulmonary artery. Currently, this technique should be reserved for very young severely ill patients, in whom ECC would be very deleterious and in type 1 isolated, small size APW, located distantly from the pulmonary artery and the semilunar valves. This type of APW would also be candidate for hemodynamic closure. (9)

In most reports transaortic closure with simple patch is preferred. In our patient with large APW as-

sociated with tetralogy of Fallot we preferred the complete separation of the arteries, with incision in the pulmonary end, favoring direct closure of the aorta without patch, with good visualization of coronary arteries and semilunar valves, based on the technique described by Van Son. (10) In our case, due to the associated disease we also had to explore and expand the pulmonary trunk with a pericardial patch.

We believe that the technique of choice in these cases is the complete separation of the APW, favoring primary closure of the aorta and using the pericardium for pulmonary artery closure. The correction of APW with associated complex lesion can be performed simultaneously with low morbidity and mortality.

**Rubén A. Toledo, Pablo R. Pérez Caram,
Alejandra Segovia, Jorge Gómez,
María S. Olivieri, Florencia Jeréz**

Sanatorio Infantil San Lucas, San Miguel de Tucumán, Argentina.
e-mail: rubenatoledo@yahoo.com.ar

REFERENCES

1. Moruno Tirado A, Santos De Soto J, Grueso Montero J, Gavilán Camacho JL, Alvarez Madrid A, Gil Fournier M, et al. [Aortopulmonary window: clinical assessment and surgical results]. *Rev Esp Cardiol* 2002;55:266-70. <http://doi.org/sxn>
2. Tkebuchava T, von Segesser LK, Vogt PR, Bauersfeld U, Jenni R, Künzli A, et al. Congenital aortopulmonary window: diagnosis, surgical technique and long-term results. *Eur J Cardiothorac Surg* 1997;11:293-7. <http://doi.org/fd72fb>
3. Kouchoukos N, Blackstone E, Doty D, Hanley F, Karp R. Aortopulmonary Window. En: Kirklin / Barrat-Boyes. *Cardiac Surgery*. 3rd ed. Philadelphia: Churchill Livingstone; 2003. p. 1223-30.
4. Backer CL, Mavroudis C. Surgical management of aortopulmonary window: a 40-year experience. *Eur J Cardiothorac Surg* 2002;21:773-9. <http://doi.org/cbsjbj>
5. Bhan A, Gupta M, Abraham S, Sharma R, Kothari SS, Juneja R. Surgical experience of aortopulmonary window repair in infants. *Interact Cardiovasc Thorac Surg* 2007;6:200-3. <http://doi.org/d3k72c>
6. Keane J, Fyler D. Aortopulmonary Window. En: Keane J, Lock J, Fyler D. *Nadas' Pediatric Cardiology*, 2nd ed. Philadelphia: Saunders Elsevier; 2006. p. 783-5.
7. Erez E, Dagan O, Georghiou GP, Gelber O, Vidne BA, Birk E. Surgical management of aortopulmonary window and associated lesions. *Ann Thorac Surg* 2004;77:484-7.
8. Castañeda A, Jonas R, Mayer J, Hamley F. Cardiac surgery of neonate and infant. Philadelphia: WB Saunders; 1994. p. 295-300.
9. Gomez J, Vieira R, Cuenca A. Successful percutaneous closure of aortic pulmonary window residual leak. *Cong Cardiol Today* 2013;11:5-8.
10. van Son JA, Hamsch J, Mohr FW. Anatomical reconstruction of aorta and pulmonary trunk in patients with an aortopulmonary window. *Ann Thorac Surg* 2000;70:674-5. <http://doi.org/bbxxnp>

REV ARGENT CARDIOL 2014;82:314-316 - <http://dx.doi.org/10.7775/rac.v82.i4.3065>

Nosocomial Infective Endocarditis Caused by Extended-Spectrum Beta-Lactamase-Producing *Klebsiella pneumoniae*

Nosocomial infective endocarditis (IE) caused by extended-spectrum beta-lactamase-producing Gram-