

Serum Lactate as Prognostic Predictor in ST-Segment Elevation Acute Myocardial Infarction

High serum lactate levels on hospital admission with static value over time are associated with higher mortality in critically ill patients. (1, 2) Lactate monitoring could detect those patients with worse prognosis, who could benefit from a more aggressive treatment. (3)

Serum lactate value has been postulated as a predictor of complications and in-hospital morbidity and mortality in patients with ST-segment elevation myocardial infarction (STEMI). (4)

The purpose of this study was to measure arterial blood lactate levels in STEMI patients at the Coronary Care Unit of Instituto de Cardiología de Corrientes Juana Francisca Cabral, on admission and at 12 hours, from 06/01/17 to 02/28/18, to assess its usefulness as prognostic marker, with follow-up until discharge from the institution.

Patients with coronary syndrome diagnosis or cardiopulmonary arrest on admission; patients with non-ST-segment elevation acute coronary syndrome or type 2, 3, 4 or 5 myocardial infarction (MI) (according to the classification of the Third Universal Definition of Myocardial Infarction); and patients with peripheral ischemia or anaphylactic, septic or hypovolemic shock and with presumed high serum lactate levels on admission were excluded from the study.

Primary endpoints were in-hospital or during the course of heart failure or cardiogenic shock mortality; secondary endpoints were days of hospitalization and troponin assessment. A total of 68 patients were included in the study; 75% were men and average age was 61.2 years. A total of 45 patients (66.2%) were hypertensive (it was the prevalent risk factor); 17 (25%) were diabetic, 20 (29.4%) had dyslipidemia, and 23 (33.8%) were smokers. The type of prevalent MI was inferior and inferodorsal with a total of 31 patients (45.6%) and extensive anterior, anterior, and anterolateral with a total of 31 patients (45.6%), consistent with the literature.

The analysis of serum lactate on admission and at 12 hours as predictor of in-hospital morbidity and mortality in the course of heart failure and cardiogenic shock showed no statistically significant differences, with a value of $p=0.078$ and $p=0.060$, respectively (Figure 1).

There was no linear correlation and no statistically significant difference between lactate levels and the number of hospitalization ($p=0.467$ lactate on admission and $p=0.503$ lactate at 12 h). Similarly, the relationship with the 1st hsTnT ($p=0.071$) and 2nd hsTnT ($p=0.211$) assessment showed no differences

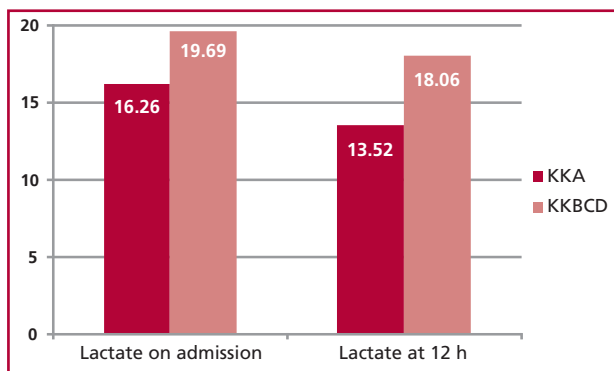


Fig. 1. The bar graph shows non-significant difference between lactate levels measured on admission and at 12 h in STEMI patients, as well as in the Killip and Kimball class present during hospitalization.

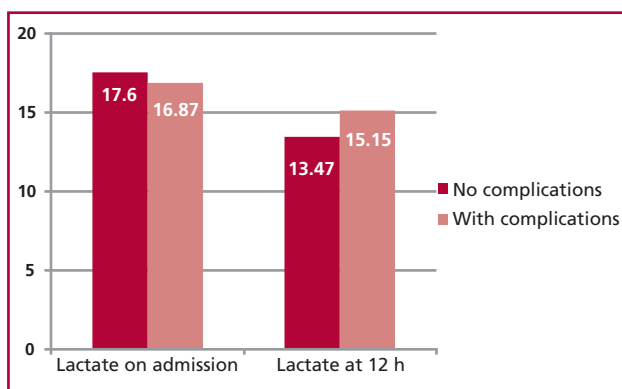


Fig. 2. The bar graph shows lactate levels measured on admission and at 12 h in STEMI patients; values subclassified as to whether or not patients presented in-hospital complications showed non-significant statistical differences.

to predict the in-hospital course.

No statistically significant differences were observed in complications in terms of lactate measurement on admission and at 12 h ($p=0.825$ and $p=0.796$, respectively) (Figure 2).

Conversely, troponin values were linearly related with the sampling time, as well as with the in-hospital course of the patient.

CONCLUSIONS

Lactate was not a predictor of diagnosis or prognosis, according to the endpoints stated for our study

Conflicts of interest

None declared.

(See authors' conflicts of interest forms on the website/ Supplementary material).

**María Paola R. Naput, Mariana A. Candia,
Mariano J. Visconti, Celeste D. Burguener,
Fernando A. Azulay, Vanina G. Singh**

Instituto de Cardiología de Corrientes Juana Francisca Cabral.
Pcia. de Corrientes - Bolívar 1334 - CP 3400.
E-mail: pao_naput@hotmail.com

Rev Argent Cardiol 2019;87:59-60. <http://dx.doi.org/10.7775/rac.v87.i1.14124>

REFERENCES

1. Attaná P, Lazzeri C, Chiostrri M, Picariello C, Gensini GF, Valente S. Lactate and lactate clearance in acute cardiac care patients. *Acute Card Care* 2012;14:20-6. <http://doi.org/cwby>
2. Kliegel A, Losert H, Sterz F, Holzer M, Zeiner A, Havel C, et al. Serial Lactate Determinations for Prediction of Outcome After Cardiac Arrest. *Medicine (Baltimore)* 2004;83:274-9. <http://doi.org/dzt2bx>
3. Cerović O, Golubović V, Spec-Marn A, Kremzar B, Vidmar G. Relationship between injury severity and lactate levels in severely injured patients. *Intensive Care Med* 2003;29:1300-5. <http://doi.org/c9pg42>
4. Vermeulen RP, Hoekstra M, Nijsten MW, van der Horst IC, van Pelt LJ, Jessurun GA, et al. Clinical correlates of arterial lactate levels in patients with ST-segment elevation myocardial infarction at admission: a descriptive study. *Crit Care* 2010;14:R164. <http://doi.org/fwz3w2>

Mechanical Thrombectomy in Moderate-Risk Pulmonary Thromboembolism

Pulmonary thromboembolism (PTE) is the third leading cause of cardiovascular death following acute myocardial infarction and stroke. Complication rates, including chronic pulmonary hypertension and right ventricular dysfunction, can be observed in up to 40% of cases. (1) Most PTE deaths occur in the first hours of the event; therefore, early management is critical.

The choice of treatment in high (massive) and moderate (submassive) risk patients is essential, as mortality can be as high as 20-50%. (2) One third of PTE patients present contraindications to thrombolytic agents, and two third of patients do not receive them for different reasons. Surgical embolectomy is a treatment option, but poor clinical status and comorbidities in patients often prevent them from being candidates to surgery. New techniques have therefore been developed, such as local thrombolysis and percutaneous catheter-directed treatment.

Today, in patients with contraindications to systemic thrombolysis and in those in whom thrombolysis has failed to improve hemodynamic stability, surgical embolectomy or percutaneous catheter-directed therapies are recommended in clinical practice guidelines. (2, 3) The purpose of these techniques is to decrease mean pulmonary artery pressure to reduce right ventricular afterload, in addition to decreasing thrombotic load and the progression to chronic pulmonary hypertension, improving patients' quality of life. However, a recent observational study showed that, due to lack of availability, only 9% of the patients received these new therapies. (4)

We describe the case of an 84-year-old female patient who was hospitalized due to anemia secondary to recently diagnosed adenocarcinoma of the colon, intercurrent with sudden dyspnea (functional class IV). Physical examination revealed tachypnea (24 breaths/min), heart rate of 140 beats per minute, blood pressure of 90/60 mmHg, oxygen saturation of 89% in ambient air with hypoventilation in both lung bases on auscultation.

Lab tests reported: hematocrit 29%, hemoglobin 9 mg/dL, creatinine 0.73 mg/dL, pro-BNP of 8000 ng/mL (normal up to 1200) and ultrasensitive troponin of 40 pg/mL (normal values <14 pg/mL). The electrocardiogram revealed acute atrial fibrillation rhythm, heart rate of 150 beats per minute, narrow QRS, and no acute ischemic ST-segment or T-wave changes.

In view of suspected PTE, a chest CT angiography was performed, which showed thrombosis in the proximal left pulmonary artery and lobar artery for the upper, middle and lower right lobes.

The echocardiography reported left ventricular ejection fraction >55%, with no regional wall motion disorders, paradoxical movement of the septum, right chamber enlargement with preserved systolic function, and estimated pulmonary systolic pressure (PSP) of 55 mmHg. The RV/LV ratio was >1.

The patient was diagnosed with moderate-to-high risk acute PTE, according to the classification of the European Society of Cardiology, with a Pulmonary Embolism Severity Index score of 184 (very high risk, class V). Anticoagulation with low-molecular weight heparin (subcutaneous enoxaparin 1 mg/kg/12 hours) was started.

After 72 hours of anticoagulant therapy, the patient showed no signs of improvement, and persisted with oxygen desaturation of 88% in ambient air in the physical examination and pulmonary hypertension in the echocardiography study.

In view of the poor course with that treatment and the high risk of recurrent bleeding, the case was discussed in a multidisciplinary panel. Pulmonary arteriography with eventual mechanical rescue thrombectomy was decided in order to reduce the pressure in the pulmonary artery in case of surgical treatment of the recently diagnosed oncological condition.

Once in the catheterization lab, the pulmonary arteriography was performed through a right femoral venous access with iodinated contrast (total 80 mL). First, baseline pressures were measured in the pulmonary artery, showing a pulmonary systolic pressure of 63 mmHg, pulmonary diastolic pressure of 21 mmHg, and mean pulmonary pressure of 35 mmHg. Then, a pulmonary arteriography revealed subtotal mural thrombus in the interlobar artery of the left lung, absence of perfusion of the lingula lobe and decreased perfusion of the lower lobe (Figure 1). A mural thrombus in the interlobar artery and occlusion of two of the branches of the middle lobe were observed

in the right lung. (Figure 1) Indigo mechanical thrombectomy (Penumbra Neuron MAX 0.88, Alameda, CA, United States) was performed on the left interlobar artery, right interlobar artery and right middle lobe with rescue of abundant –organized– thrombotic material (Figure 2). Follow-up angiography following thrombectomy showed improved pulmonary perfusion (Figure 3).

The patient was asymptomatic for dyspnea during the immediate postoperative course, with oxygen saturation of 96% in ambient air. Laboratory tests reported: hemoglobin 9.2 g/dL and hematocrit 29%. Echocardiography revealed a decrease in PSP from 33 mmHg to 20 mmHg. It was decided to continue with low-molecular weight heparin.

Catheter-directed endovascular treatments are increasingly used in patients with PTE who are at high risk for bleeding complications with systemic thrombolysis. These approaches include mechanical thrombolysis and local ultrasound-assisted thrombolysis. The latter is the only invasive treatment approved by the FDA. Mechanical thrombectomy is an increasing-

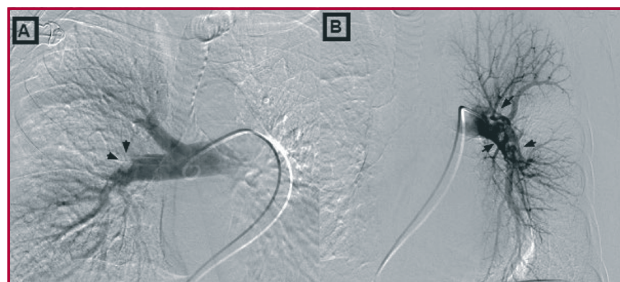


Fig. 1. Diagnostic angiography showing: **A:** Right lung: Mural thrombus in the interlobar artery (arrow) and occlusion of two middle lobe branches. Absence of middle lobe perfusion; **B:** Left lung: Interlobar artery with subtotal thrombosis (arrow) and marked decrease of lower lobe and lingula lobe perfusion.



Fig. 2. Rescue of organized (red thrombus) and disorganized (white thrombus) thrombotic material following mechanical thrombectomy.

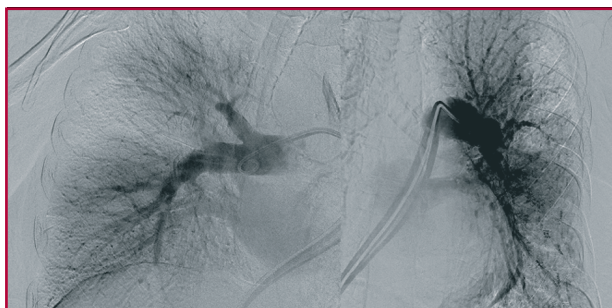

Fig. 3. Pulmonary angiography after mechanical thromboaspiration.

ly important technique for patients with massive and submassive PTE, who are contraindicated to (local or systemic) fibrinolytics, or for patients with high-risk or massive PTE who do not respond to systemic thrombolytic therapy. (6)

We described this case as an example of a state-of-the-art treatment used in a patient with submassive PTE and absolute contraindication to anticoagulation. In these patients with PTE and right ventricular dysfunction, early treatment may prevent deterioration of RV function and decrease signs and symptoms. In our case, mechanical thrombectomy was chosen to improve the patient's symptoms and optimize right ventricular loads in order to perform a curative treatment of her oncological disease.

The Penumbra System is a mechanical thrombectomy device designed to reduce peripheral and brain thrombus load located in arteries or veins. It consists of a mesh catheter with multiple flexibility transitions, especially designed for thrombus aspiration while providing continuous vacuum of the pump. It allows direct thrombus aspiration, avoiding fragmentation and distal dissemination. Close contact with the thrombus is very important to prevent blood loss through the aspiration mechanism. In our patient, no alterations of hemoglobin or hematocrit were observed after the procedure.

Today, patients with moderate-high risk PTE and contraindications to conventional treatments are exposed to the free progression of the disease, which can be unfavorable and implies high morbidity and mortality. These patients need to be treated more aggressively, as anticoagulation is often not enough to improve the patient's prognosis.

We believe that the importance of presenting cases such as this one lies in highlighting the significance that new endovascular technologies are gaining in patients with moderate-high risk PTE and contraindications to thrombolytics, in order to consider them as promising options for future treatment.

Conflicts of interest

None declared.

(See authors' conflicts of interest forms on the website/ Supplementary material).

Juan I. Damonte¹, Ignacio Seropian²,
Carlos Rojas Matas², Ignacio Bluro¹,
Anibal Arias¹, Rodolfo Pizarro¹

¹ Department of Cardiology,
Hospital Italiano de Buenos Aires, CABA, Argentina.
² Department of Interventional Cardiology,
Hospital Italiano de Buenos Aires, CABA, Argentina.
Hospital Italiano de Buenos Aires Coronary Care Unit.
Perón 4190, C1199ABB - CABA
Phone +5491149590200, extension 8920/8921
Fax +5491149590200, extension 8758

Rev Argent Cardiol 2019;87:60-62. <http://dx.doi.org/10.7775/rac.v87.i1.12303>

REFERENCES

1. Pengo V, Lensing AW, Prins MH, Marchiori A, Davidson BL, Tiozzo F, et al; Thromboembolic Pulmonary Hypertension Study Group. Incidence of chronic thromboembolic pulmonary hypertension after pulmonary embolism. *N Engl J Med* 2004;350:2257-64. <http://doi.org/dkwfv8>
2. Jaff MR, McMurtry MS, Archer SL, Cushman M, Goldenberg N, Goldhaber SZ, et al Management of Massive and Submassive Pulmonary Embolism, Iliofemoral Deep Vein Thrombosis, and Chronic Thromboembolic Pulmonary Hypertension. *Circulation*. 2011;123:1788-830. <http://doi.org/fgnx8w>
3. Konstantinides SV, Torbicki A, Agnelli G, Danchin N, Fitzmaurice D, Galie N, et al. 2014 ESC Guidelines on the diagnosis and management of acute pulmonary embolism. *Eur Heart J*. 2014;35:3033-69. <http://doi.org/9vr>
4. Kearon C, Akl EA, Comerota AJ, Prandoni P, Bounameaux H, Goldhaber SZ, et al. Antithrombotic therapy for VTE disease: anti-thrombotic therapy and prevention of thrombosis: American College of Chest Physicians evidence-based clinical practice guidelines. *Chest* 2012;141:e419S-494. <http://doi.org/cbcpk>
5. Pereira CF, Curotto V, Rodríguez Pagani C, Renes M, Rodríguez A, et al. Percutaneous Rheolytic Embolectomy for Massive Pulmonary Embolism. *Rev Argent Cardiol* 2010;78:442-4.
6. Kabrhel C, Rosovsky R, Channick R, Jaff MR, Weinberg I, Sundt T, et al. A Multidisciplinary Pulmonary Embolism Response Team: Initial 30-Month Experience With a Novel Approach to Delivery of Care to Patients With Submassive and Massive Pulmonary Embolism. *Chest*. 2016;150:384-93. <http://doi.org/cvppv>

Brugada Phenocopy

“Hyperkalemia Mimicking a Brugada Syndrome Pattern”

We describe the case of a 55-year-old patient, with no history of heart disease, with hypertension and type-2 diabetes, bronchial asthma, and probable pulmonary neoplasm under study.

The patient was admitted in the coronary care unit under mechanical ventilation, in the context of an acute asthmatic crisis. Lab tests on admission reported potassium (K) 8.4 mEq/L, sodium 142.4 mEq/L, and creatinine 4 mg/%. The admission electrocardiogram showed sinus rhythm at 100 bpm, PR interval 200 ms and a right branch conduction disorder with transient ST-segment elevation >2 mm, type-1 cove-shaped Brugada pattern in leads V1, V2, and 1 mm in lead V3, consistent with type-2 Brugada pattern (Figure 1). (1) On admission, the condition was interpreted as a general metabolic disorder, and a possible acute ischemic event was ruled out since laboratory results were available at

the time of admission to the coronary care unit. Acute renal failure was diagnosed and treatment with i.v. calcium gluconate and emergency hemodialysis were initiated. After aberrant nodal rhythm was reached at a heart rate of 30 bpm with K of 9.5 mEq/L at the time of dialysis, normalization of the right branch intraventricular conduction disorder was achieved, as well as

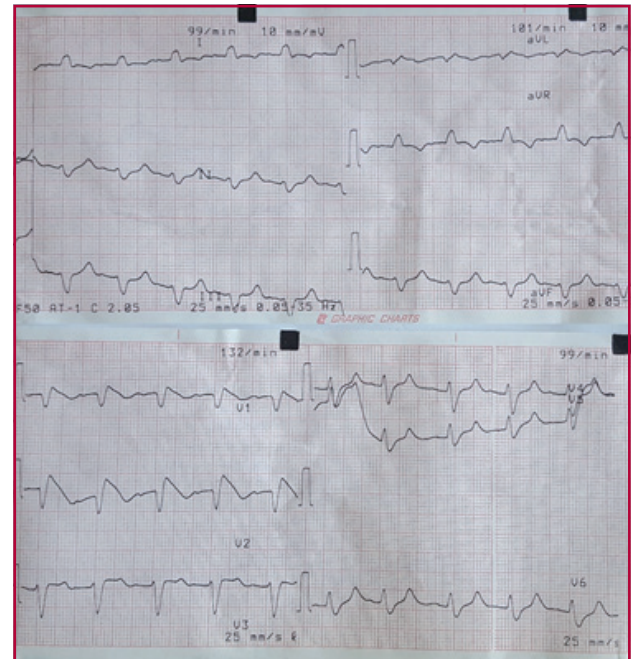


Fig. 1. BrP, potassium 8.4 mEq/L

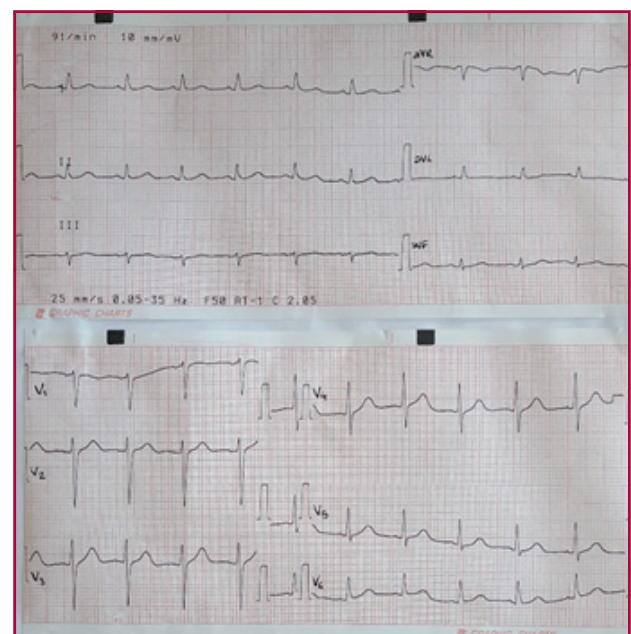


Fig. 2. Normal ECG, potassium 3.8 meq/L

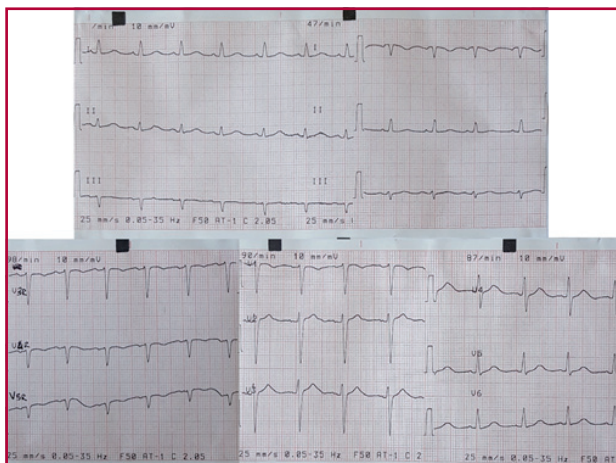


Fig. 3. Negative flecainide testing

normalization of the PR interval when normal K levels were obtained (Figure 2).

Similar cases of Brugada phenocopies (BrP) have been reported in the world literature, described as different clinical situations that may present the characteristic type-1 or type-2 Brugada patterns in the absence of the true syndrome, and once the clinical situation is resolved, temporary changes in the ST-T disappear, returning to the basal ECG. (2) Up to now, six categories that induce BrP have been described: metabolic and mechanical conditions, myocardial ischemia and pulmonary embolism compression, myocardial and pericardial disease, ECG modulations and miscellaneous causes.

The cascade of progressive ECG changes caused by developing hyperkalemia coincides with the case described. Initially, increased voltage and decreased symmetrical and peaked T-wave duration were found in the ECG of our patient. We then found sinus bradycardia with P-wave flattening, as manifestation of the normal electrical impulse generation disorder; atrioventricular and then intraventricular conduction disorder, with -usually right- bundle branch blocks, aberrant nodal rhythm at low heart rate, until finally ventricular fibrillation before starting dialysis. (3)

Many of the disorders caused by hyperkalemia were observed and recorded in our patient, but disappeared after normalization of potassium levels.

Flecainide testing was performed after several days of renal function and serum K level stability, with a negative result (Figure 3). For this reason, we consider that ECG manifestations in our patient were consistent with BrP secondary to hyperkalemia in the context of acute kidney failure. (4)

Conflicts of interest

None declared.

(See authors' conflicts of interest forms on the website/ Supplementary material).

**Leonardo M. Hail, Carlos A. Giudici Costa,
Ricardo A. Migliore**

Department of Cardiology, HIGA Eva Perón, San Martín,
Pcia. de Buenos Aires, Argentina
E-mail: leonardomartinhail@gmail.com
Phone: 0054-11-6591-3055

Rev Argent Cardiol 2019;87:62-63. <http://dx.doi.org/10.7775/rac.v87.i1.14129>

REFERENCES

1. Bayés de Luna A, Brugada J, Baranchuk A, Borggreffe M, Breithardt G, Goldwasser D, et al. Current electrocardiographic criteria for diagnosis of Brugada pattern: a consensus report. *J Electrocardiol* 2012;45:433-42. <http://doi.org/f36m2h>
2. Anselm DD, Baranchuk A. Fenocopia de Brugada: surgimiento de un nuevo concepto. *Rev Esp Cardiol* 2013;66:755. <http://doi.org/f2ff2m>
3. Kovacic JC, Kuchar DL. Brugada pattern electrocardiographic changes associated with profound electrolyte disturbance. *Pacing Clin Electrophysiol* 2004;27:1020-3. <http://doi.org/b65dgw>
4. Meregalli PG, Ruijter JM, Hofman N, Bezzina CR, Wilde AA, Tan HL. Diagnostic value of flecainide testing in unmasking SCN5A-related Brugada syndrome. *J Cardiovasc Electrophysiol* 2006;17:857-64. <http://doi.org/cx2nms>

Superior Thyroid Artery Pseudoaneurysm Secondary to Jugular Vein Catheter Cannulation

Complications during central venous catheter placement are uncommon and their incidence has decreased further with the use of ultrasound guidance for venous puncture. Inadvertent arterial puncture with a small needle during venous catheterization usually causes mild morbidity in 5% of cases (0% to 11%). (1, 2) The most commonly involved artery is the common carotid artery. (2, 3) However, complications due to iatrogenic arterial trauma during venous catheterization can be severe and even fatal, including massive bleeding, airway obstruction by cervical hematoma, shock from hemothorax, arterial thrombosis or dissection, embolism, pseudoaneurysm, arteriovenous fistula, stroke and death. (1, 2)

We report the case of a 73-year-old male patient with history of hypertension and 5-year history of paroxysmal atrial fibrillation (AF), who had had several hospitalizations due to AF recurrence despite different drug-therapy schemes. Radiofrequency ablation by venous puncture via right femoral artery and right jugular artery was performed, taking into account only the anatomical landmarks, with no ultrasound guidance.

The patient was discharged on the second day, under treatment with aspirin 100 mg/day and apixaban 10 mg/day, presenting slight hematoma at the puncture sites without clinical repercussion.

Three months after the procedure, the patient consulted for progressive growth of a painless right

submaxillary pulsating tumor. Ultrasound revealed flow within a 30 × 28 mm saccular image, consistent with pseudoaneurysm associated to the right common carotid artery. Since the patient was under anticoagulation therapy with apixaban, anatomical characterization of the image with computed tomography angiography of the neck vessels was performed, evidencing flow within a 30-mm-diameter pseudoaneurysmal dilatation originated in the superior thyroid branch of the external right carotid artery (Figure 1).

Endovascular treatment was decided using superselective embolization of superior thyroid artery branches with platinum-fiber micro-coils, achieving the total exclusion of the pseudoaneurysm without complications. Follow-up Doppler echocardiography at 4 months showed completely thrombosed pseudoaneurysm.

Risk factors for complications of iatrogenic arterial puncture include anatomical variations, obesity, history of neck surgery or previous catheters, operator inexperience, extreme rotation of the neck, multiple puncture attempts, large-caliber needle, coagulopathy, diseased artery, and low adherence to the Seldinger technique. (4)

Prevention of arterial injury has been focused on the operator expertise and the use of ultrasound guidance during central venous catheter placement. A meta-analysis of randomized controlled trials indicates that, compared to the anatomical landmark-guided technique, ultrasound-guided venipuncture of the internal jugular vein has a higher success rate at first insertion, shorter access time, higher success rate of venous cannulation and low rate of arterial puncture. (4)

Cervical pseudoaneurysm is a rare complication and it generally occurs in the internal carotid artery, with few reports of pseudoaneurysm in the superior thyroid artery. The seven cases published in the literature, while different in their etiology, have been successfully treated with endovascular coil embolization. (See Table 1) (2, 3, 5, 8)

Arterial pseudoaneurysms generally increase in size and present as a pulsating tumor in the cervical region; other clinical manifestations include hematoma, dysphagia, hoarseness, and neurologic deficits of the cranial pairs. (2, 3)

Doppler ultrasound of the neck vessels is the main non-invasive imaging method to confirm the diagnosis, followed by computed tomography angiography, which allows for better characterization of this type of vascular lesions in deeper neck regions. While conventional angiography is not a routine technique for the diagnosis of pseudoaneurysm, it is used after non-invasive methods as it is the most sensitive technique for defining the exact location of the injured artery and for detecting associated arteriovenous fistula.

The therapeutic options for a pseudoaneurysm include ultrasound-guided compression, percutaneous thrombin injection, conventional surgical exclusion

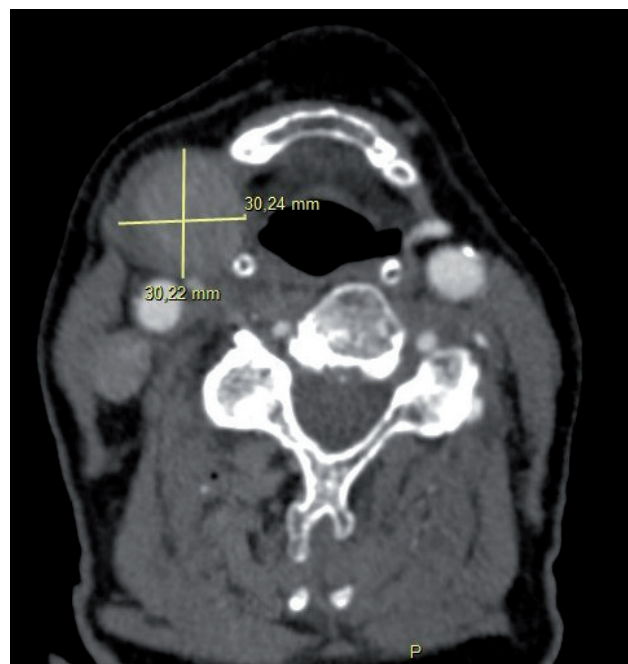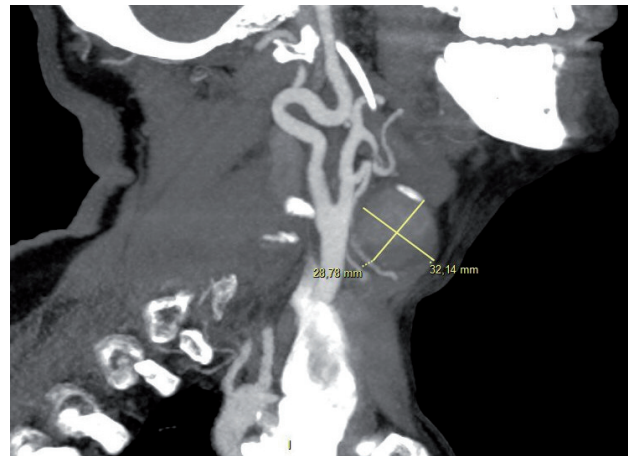


Fig. 1. a & b. Computed tomography angiography of the neck vessels showing a 30-mm-diameter pseudoaneurysm originated in the superior thyroid branch of the external right carotid artery.

and endovascular therapy by embolization. (2, 3)

In some studies, and in cases of small pseudoaneurysms, conservative management has been described, as spontaneous closure of iatrogenic pseudoaneurysms has been observed during follow-up in up to 89% of cases. (9) However, treatment was decided in our patient due to the pseudoaneurysm size and anatomical location, and to the fact that the patient was under anticoagulant therapy. Since the pseudoaneurysm was located in the cervical region and due to the lack of underlying bone landmark to perform an effective ultrasound-guided compression, that therapeutic option was not considered. Percutaneous thrombin injection was not an option either because of the potential risk of inadvertent embolization of intracranial thrombin.

Table 2. Location of IE

	Lesion mechanism
Wang, <i>et al</i>	Stab wound (2 cases reported)
Perona, <i>et al</i>	Ultrasound-guided chemical parathyroidectomy
Ernemann, <i>et al</i>	Radiation therapy for laryngeal cancer
Celik, <i>et al</i>	Fine needle puncture of thyroid node
Canevari, <i>et al</i>	Cardioversion guided by transesophageal echocardiography
Khera, <i>et al</i>	Internal jugular venous puncture

Endovascular treatment by embolization has proved to be a safe and effective technique in this pseudoaneurysm location. (2, 3, 5-8) Conventional resection or exclusion of pseudoaneurysm has greater morbidity associated with lesions of peripheral nerves and cranial pairs, wound complications and cosmetic defects of facial scars; therefore, surgical treatment is considered only if embolization is not effective.

Conflicts of interest

None declared.

(See authors' conflicts of interest forms on the website/ Supplementary material).

**Mariano Norese,
Emiliano Lucas Rojo,
Juan Manuel Souto,
Gustavo Andersen**

Clínica Bazterrica - C.A.B.A

Juncal 3002 Ciudad Autónoma de Buenos Aires. (C.P 1425)

E-mail: marianonorese@hotmail.com

Rev Argent Cardiol 2019;87:63-65. <http://dx.doi.org/10.7775/rac.v87.i1.12303>

REFERENCES

1. Guilbert MC, Elkouri S, Bracco D, Corriveau M, Beaudoin N, Dubois MJ, et al. Arterial trauma during central venous catheter insertion: Case series, review and proposed algorithm. *J Vasc Surg* 2008;48:918-25. <http://doi.org/fnd2kr>
2. Khera S, Moses V, Ahmed M, Kakde S. Superior thyroid artery pseudoaneurysm and arteriovenous fistula following attempted internal jugular venous access and its management. *Indian J Radiol Imaging* 2015;25:15-7. <http://doi.org/cwxc>
3. Wang D, Su L, Han Y, Fan X. Embolization treatment of pseudoaneurysms originating from the external carotid artery. *J Vasc Surg* 2015;61:920-6. <http://doi.org/f664bs>
4. Bansal R, Agarwal SK, Tiwari SC, Dash SC. A prospective randomized study to compare ultrasound-guided with nonultrasound-guided double lumen internal jugular catheter insertion as a temporary hemodialysis access. *Ren Fail* 2005;27:561-4. <http://doi.org/dgsqzd>
5. Canevari FR, Martines F, Sorrentino R, Nicolotti M, Sireci F. Pseudoaneurysm of superior thyroid artery following a transesophageal echocardiography: a case presentation. *Euromediterranean Biomed Journal* 2017;12:10-2.
6. Ernemann U, Herrmann C, Plontke S, Schäfer J, Plasswilm L, Skalej M. Pseudoaneurysm of the superior thyroid artery following radiotherapy for hypopharyngeal cancer. *Ann Otol Rhinol Laryngol* 2003;112:188-90. <http://doi.org/cwxd>
7. Perona F, Barile A, Oliveri M, Quadri P, Ferro C. Superior thyroid artery lesion after US-guided chemical parathyroidectomy: angiographic diagnosis and treatment by embolization. *Cardiovasc Intervent Radiol* 1999;22:249-50. <http://doi.org/d657rk>
8. Celik H, Yücel C, Oktar S, Karadag Z, Ozdemir H. Iatrogenic pseudoaneurysm of the superior thyroid artery: color Doppler ultrasonographic diagnosis and treatment approach. *J Ultrasound Med* 2004;23:1675-8. <http://doi.org/cwxf>
9. Toursarkissian B, Allen BT, Petrincec D, Thompson RW, Rubin BG, Reilly JM, et al. Spontaneous closure of selected iatrogenic pseudoaneurysms and arteriovenous fistulae. *J Vasc Surg* 1997;25:803-8. <http://doi.org/d6vg3d>